

# Post-surgical wound management of pilonidal cysts by using a haemoglobin spray

**Nesat Mustafi<sup>1</sup> & Peter Engels<sup>2</sup>** <sup>1</sup>Wound center, Northwest Hospital, Frankfurt, Germany, <sup>2</sup>Bergisch Gladbach, Germany

**Objective:** Painful acute cysts in the natal cleft or lower back, known as pilonidal sinus disease, are a severe burden to many younger patients. Although surgical intervention is the preferred first line treatment, post-surgical wound healing disturbances are frequently reported due to wound infection or other complications. Although different treatment options of pilonidal cysts have been discussed in the literature, no standardized guideline for the post-surgical wound treatment is currently available. After surgery, a common recommended treatment to patients is rinsing the wound with clean water and dressing with a sterile compress.

- Here we present a case series of seven patients with wounds healing by secondary intention after surgical intervention of a pilonidal cyst using haemoglobin spray as adjunctive treatment for local oxygen delivery.<sup>1</sup>
- The main goal of the retrospective analysis was to carve out a robust and easy to apply protocol with respect to fast wound closure, avoidance of healing disturbances or restarting wound healing of stagnating wounds by to improve the topical oxygen delivery.
- A second goal was to evaluate the benefit with respect to the aesthetic results of scar tissue.

# Results

Case	Age	Gender	Wound condition			Time from surgery to first visit at Wound Care Centre	Treatment time at Wound Care Centre	No. of dressing changes	Wound healing	Cosmetic quality of scar tissue	Recurrence			
			Fibrin	Healing disturbance	Infection of pilonidal cyst						Days	Days		after 3 months
1	24	Female	No	No	Yes	5	70	15	Yes	excellent	No	No	No	
2	51	Male	Yes	No	Yes	6	97	26	Yes	moderate	No	No	No	
3	58	Female	No	No	No	2	98	24	Yes	excellent	No	No	No	
4	49	Male	Yes	Yes	Yes	50	152	43	Yes	poor	No	No	yes*	
5	30	Male	Yes	Yes	Yes	43	23	5	Yes	excellent	No	No	n.d.	
6	39	Female	Yes	Yes	Yes	40	59	9	Yes	excellent	No	No	n.d.	
7	27	Male	No	No	No	2	32	6	Yes	excellent	No	n.d.	n.d.	
Median	39					6	70	15						
Average	40					21	76	18						
SD	13					22	44	14						
						n.d. = not determined			*small fistula, closed within 3 weeks					

Seven cases of secondary healing wounds after complete excision of the pilonidal cysts are described.

- ❖ Average age of the patients was 39 years and four patients were 39 or older.
- ❖ 5 out of 7 patients had an infection
- ❖ 3 of 7 showed a wound healing disturbance of at least five weeks.

# Wound Treatment

When patients showed up at the wound centre, an initial wound inspection was conducted. Dependent on the wound situation, the following **Wound Care Protocol** was applied:

❖ **Protocol A (cases 1 to 4):**

- Mechanical debridement of fibrous coating and necrotic tissue if required,
- Rinsing with an antimicrobial irrigation solution;
- Application of haemoglobin spray;
- Application of a primary dressing (alginate) if required during exudation phase and as long as cavities and wound pockets existed to prevent superficial wound closure;
- Application of a secondary absorbent dressing (compress or hydropolymer dressing).

❖ **Protocol B (cases 5 to 7):**

- In the first week, wound treatment was repeated every second day.
- Autolytic debridement followed by hydrofiber foam,
- Rinsing with an antimicrobial irrigation solution,
- Mild laser therapy was performed for 15 minutes,
- Application of the haemoglobin spray,
- Primary tamponade (absorbent foam) as long as cavities and wound pockets existed to prevent superficial wound closure,
- Secondary foam dressing .

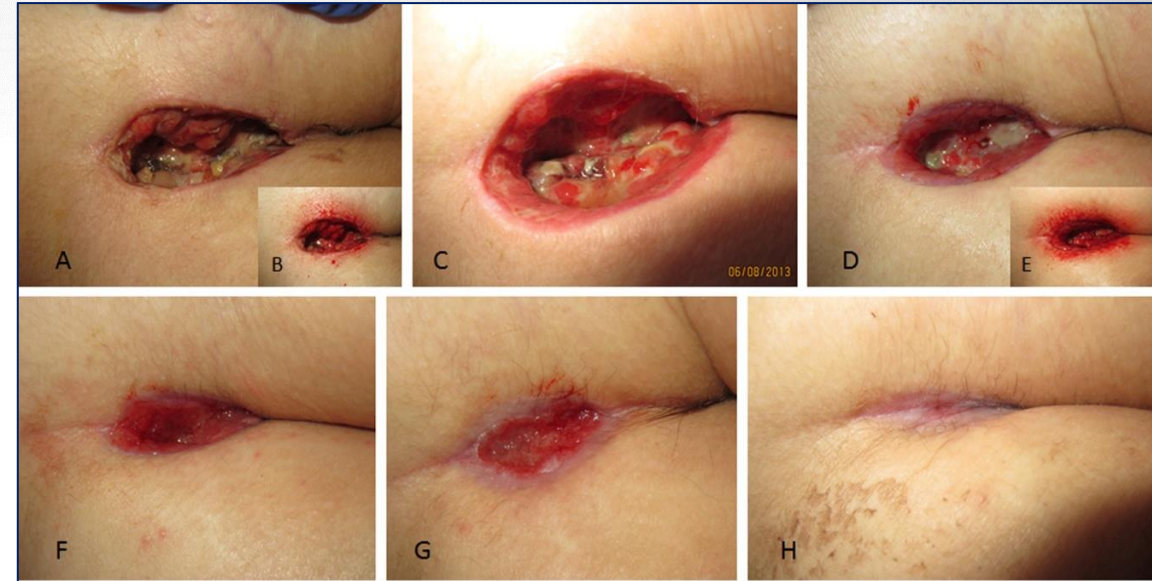After the first week, treatment frequency was changed to once a week without autolytic debridement. The treatment protocol and intervals of treatment were adapted during the treatment period accordingly.

- ❖ ***Additional wound care*** : To avoid any further inflammation by ingrowing hair, hair was removed at the wound border if necessary. No other care or aftercare after wound closure was applied.

# Results

## Case 1: 24-year old female patient with a painful abscessing pilonidal sinus

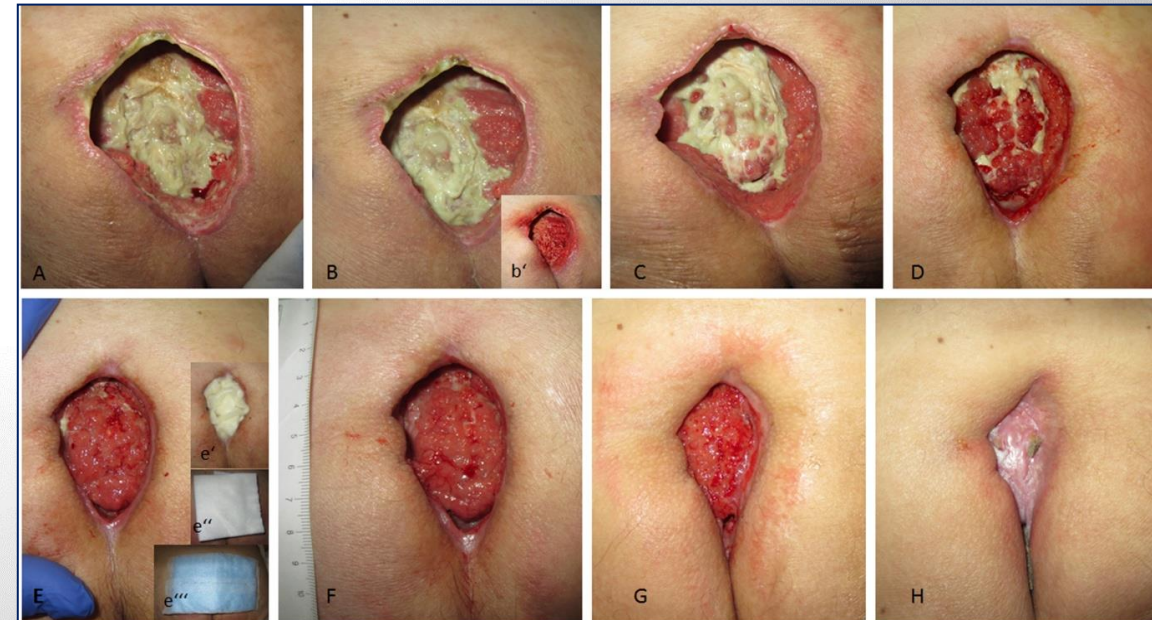
- ❖ Surgical excision of the complete pilonidal cyst without plastic covering
- ❖ Wound treatment according to wound care protocol A
- ❖ First week: 3 times per week wound treatment with a mechanical debridement (A,B).
- ❖ Second to fourth week twice a week wound treatment without mechanical debridement (C,D)
  - Alginate tamponade was applied to avoid superficial wound closure and wound infection.
- ❖ After four weeks once per week wound treatment (F, G) as granulation tissue filled up the wound cavity and treatment
- ❖ Full closure of the wound with excellent cosmetic skin quality was achieved after 70 days (H).
- ❖ The patient reported no recurrence at 9 months after wound closure.



## Case 4: 49-year old male patient with stagnating wound healing 6 weeks after surgical excision of abscessing pilonidal sinus and deep revision of the wound after 4 weeks.

Post-surgical wound rinsing with tap water and covering by a sterile compress at home.

- ❖ Wound treatment according to wound care protocol A
- ❖ Week one to eight: wound treatment with a sharp mechanical debridement (A,B) 3 times/week
- ❖ Week nine to thirteen: wound treatment without mechanical debridement (C,D) twice a week
  - Alginate tamponade was applied to avoid superficial wound closure and wound infection.
- ❖ After thirteen weeks once per week wound treatment (F, G)
- ❖ Full closure of the wound with poor cosmetic skin quality was achieved after 152 days (H).
- ❖ No recurrence at 6 months after wound closure. After 8 months a small wound was obtained at the distal part, closed within 3 weeks with similar wound care protocol as applied before.



# Discussion & Conclusion

- ❖ All seven patients exhibited successful wound closure with a median of 70 days (average 76 days, table 1).
- ❖ No recurrence of healed wounds was reported by any of the patients at 3 months after wound closure (phone interview or personal visit), and for 5 patients after 6 months while one case of recurrence was reported after 9 months (table 1, Case 2).
- ❖ Three cases treated within the first 6 days after excision revealed an excellent scar tissue quality, while one result was classified as moderate. In two cases with mild to severe healing disturbances an excellent cosmetic tissue result was achieved.
- ❖ One case with a severe healing disturbance revealed an extended healing time (152 days) with a poor aesthetic result.

## Conclusion

- 1) To avoid healing disturbances of wounds healing by secondary intention after surgical pilonidal cyst intervention an adequate wound care regimen comprising appropriate wound debridement, rinsing, topically applied haemoglobin and adequate wound dressing is recommendable as early as possible after surgery.
- 2) As oxygen plays an essential role in all phases of wound healing, the application of a haemoglobin spray as oxygen shuttle should be an integral part of the treatment protocol to achieve an enhanced wound healing and obtain improved aesthetic results.