

G. CAZANDER<sup>1</sup>, F. GOTTRUP<sup>2</sup>, G.N. JUKEMA<sup>1</sup>

1. Department of Trauma Surgery, VU University Medical Center, Amsterdam, The Netherlands.

2. Copenhagen Wound Healing Center, Bispebjerg Hospital, Copenhagen, Denmark.

# Maggot therapy for wound healing: clinical relevance, mechanisms of action and future prospects

## Abstract

The maggots of *Lucilia sericata* are especially indicated for severe, infected wounds that need debridement. Maggot Debridement Therapy (MDT) was a well-known therapy in ancient war times and was successfully reintroduced in the 1990s for treatment of infected wounds. MDT was approved by the FDA in 2004 (510(k) #33391). The exact mechanism of action of MDT is unknown, although part of the underlying mechanism could be explained by modification of extracellular matrix components and by biofilm reduction. Maggots and/or their excretions and secretions (ES) do not possess direct antibacterial properties. However, there seems to be an immune-related effect of maggot ES, which results in the inhibition of the pro-inflammatory response. This review provides an overview of the clinical indications for the use of maggots, discusses the leading hypotheses about the underlying mechanism of action of MDT in the literature and suggests some possible future prospects.

**Key words:** Cost-effectiveness, Debridement, Economics, Hydrosurgery, Versajet®, Water dissection, Wound healing, Wound technology

## Introduction

The beneficial effects of maggots in the wound healing process have been known for centuries. For the past ten years, maggot debridement therapy (MDT) has been used in clinical practices in Europe and the US for the treatment of various types of severely infected wounds with successful healing results.<sup>1,2</sup> Several historic documents prove that in ancient times maggots, also known as 'bio-surgeons', were already applied for wound treatment.<sup>3</sup> The Aborigines in Australia and Maya tribes in Central America used larvae frequently to clean wounds. Ambroise Paré (1510-1590), a French military surgeon, and Baron Dominique Larrey (1766-1842), surgeon of Napoleon, reported their observations of injured soldiers who had clean wounds that healed quickly during the colonization of maggots.<sup>3,4</sup> Many surgeons confirmed the observations of Paré and Larrey, but William Baer (1872-1931), orthopaedic surgeon at the Johns Hopkins Hospital in Baltimore was the first surgeon to employ larvae of the *Lucilia sericata* for the treatment of children with osteomyelitis in 1929.<sup>5</sup> Baer described a fast debridement, the reduction in bacterial counts, decreased odour and alkalinisation of the wound surface. Until the 1940s American surgeons used MDT, but the discovery of penicillin by Alexander Fleming in 1928 and the widespread production and use of this first antibiotic from 1944 onwards led to the disappearance of maggots as a treatment for infected wounds.<sup>6,7</sup> However, just 4 years after the introduction of penicillin, more than 50% of all *S. aureus* specimens produced  $\beta$ -lactamase, which made them resistant to the mould.<sup>7</sup> Antibiotic resistance to penicillin, and also to other types of antibiotics, increased thereafter, which resulted in the failed healing of infections and due to this, maggots made their comeback in the late 1980s.<sup>8</sup> In the following years, MDT was reintroduced in hundreds of clinics in the US and Europe.<sup>9-11</sup> Since the approval of MDT as a debride-

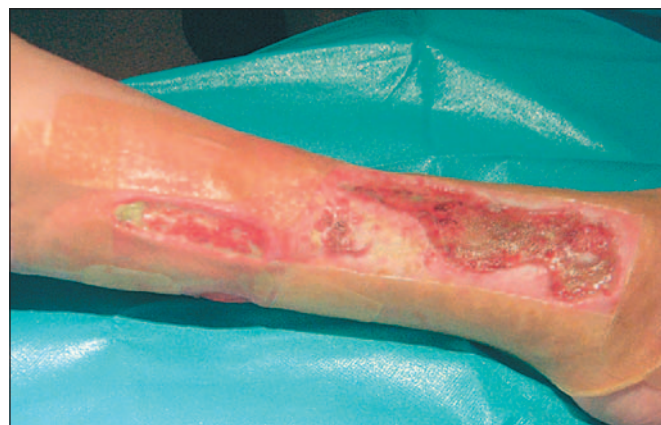

Figure 1. A 76-year-old patient suffering from osteomyelitis of the tibia

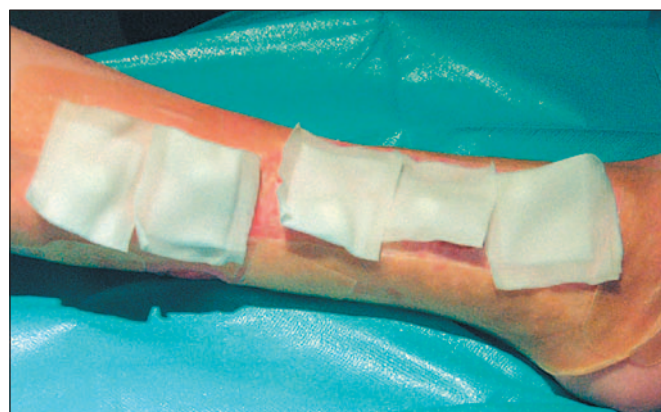

Figure 2. Debridement of the wound surface by maggot therapy using *Lucilia sericata* captured in special bags

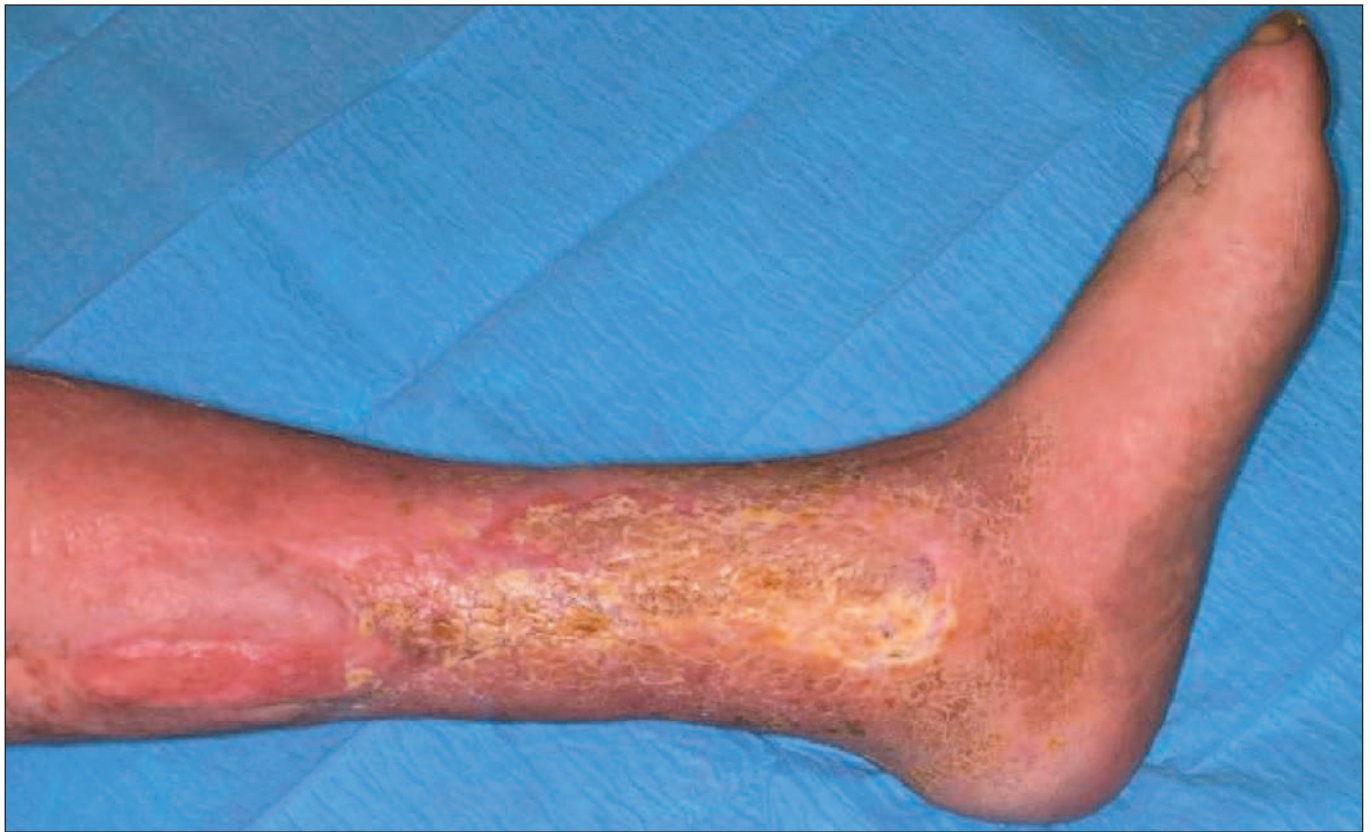

Figure 3. Healing and wound closure after mesh graft transplantation

ment therapy, by the US Food and Drug Administration (510(k) #33391) in 2004<sup>12</sup>, maggots of *Lucilia sericata* have been widely used to treat infected wounds.<sup>13-15</sup> The aim of this review is to describe the indications for the use of maggots, the effect of MDT in debridement and the underlying mechanisms of action of MDT which are reported in the literature.

### Clinical indications and mode of applications

MDT can be used for acute and chronic wound infections. In the literature the reported success rate varies from 80 to

90%.<sup>16</sup> The FDA describes the indications for MDT as follows: "For debriding non-healing necrotic skin and soft tissue wounds, including pressure ulcers, venous stasis ulcers, neuropathic foot ulcers, and non-healing traumatic or post surgical wounds." More specifically, several case reports and case series show clinical relevance for improved wound healing by the use of maggots, e.g. in diabetic ulcers, ischaemic leg ulcers, osteomyelitis (Figure 1-3), burn wounds, as postoperative treatment for a necrotizing fasciitis or for the prevention of [further] amputations.<sup>8,11,16-17</sup> (Table 1). More unusual indications

→

Common indications in the case of infection	Unusual indications	Contra-indications	Side effects
<ul style="list-style-type: none"> <li>Wound debridement</li> <li>Ulcers<sup>1</sup></li> </ul>	<ul style="list-style-type: none"> <li>Necrotic tumors</li> <li>Sub-acute mastoiditis</li> </ul>	<ul style="list-style-type: none"> <li>Open wounds in abdominal cavity</li> </ul>	<ul style="list-style-type: none"> <li>Tickling feeling (often)</li> <li>Pain (sometimes)</li> </ul>
<ul style="list-style-type: none"> <li>Non-healing traumatic wounds</li> <li>Burn wounds</li> <li>Post surgical wounds</li> </ul>	<ul style="list-style-type: none"> <li>Cutaneous leishmaniasis</li> <li>Debridement of uncommon places<sup>2</sup></li> </ul>	<ul style="list-style-type: none"> <li>Wounds near to large blood vessels</li> <li>Septic arthritis</li> </ul>	<ul style="list-style-type: none"> <li>Transient pyrexia (rare)</li> <li>Bleeding (rare)</li> </ul>
<ul style="list-style-type: none"> <li>Osteomyelitis</li> </ul>	<ul style="list-style-type: none"> <li>(Wound treatment in palliative setting)</li> </ul>	<ul style="list-style-type: none"> <li>Pyoderma gangrenosum (with the use of immunosuppressive therapy)</li> </ul>	

Table 1. Overview of (contra-) indications for MDT and side effects

1. Including pressure ulcers, neuropathic and diabetic ulcers, venous and arterial ulcers. 2. Pleural cavity, glans penis, perineal, gynaecological wounds

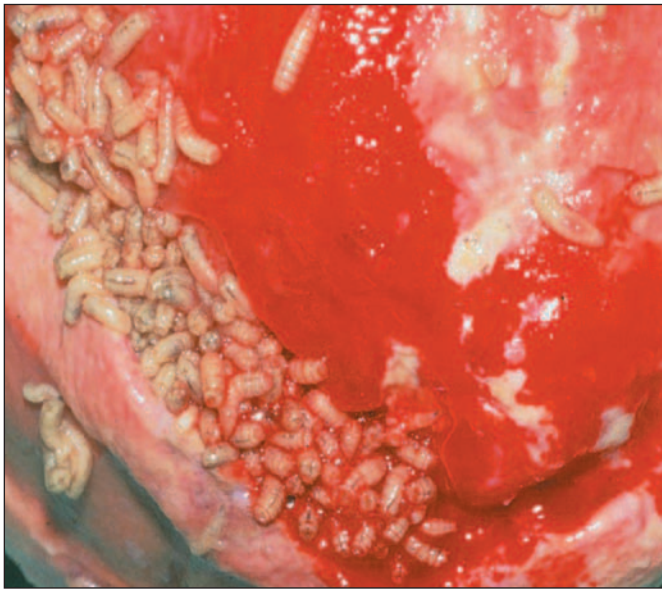


Figure 4. Wound infection: treatment with maggots (Instar 3, after 4 – 5 days) of *Lucilia sericata* using a free-range technique




Figure 5. Maggots of the *Lucilia sericata* (Instar 1-2 larvae after 24 - 48 hours) enclosed in a Biobag®

→ and recorded off-label applications for which MDT has shown successful effects include necrotic tumours, perineal wounds after (gynaecological) surgery, cutaneous leishmaniasis, subacute mastoiditis and debridement of uncommon sites (e.g. glans penis, pleural space).<sup>18-21</sup> In principle, the aim of MDT is to improve wound healing by stimulation of proliferating granulation tissue, but maggots can also be used to reduce pain, odour and prevent further progress in chronic wound infections, especially in a palliative setting.<sup>22</sup> The efficacy of MDT for several indications based on clinical reports is listed in *Table 2*. Currently, there are two modes of application of MDT. First, freely crawling larvae can be applied to the wound bed then covered by a gauze bandage to keep them captured (*Figure*

4). Today in many clinics, a second mode of application of maggots is preferred. The maggots are captured and enclosed in special Biobags® (Biomonde GmbH, Barsbüttel, Germany) that consist of a sterile nylon gauze network, with a foam dressing containing a polyvinyl alcohol spacer<sup>23</sup> (*Figure 5-7*). The network of the Biobag® is permeable and permits the migration of maggot excretions/secretions (ES) to the wound. This bag facilitates the application of MDT, but also the inspection of the wound bed during the treatment at any time. The effectiveness of the MDT captured in bags or in free-range application seems to be equal<sup>24</sup> but in the case of complicated cavity wounds, free larvae may be preferable. We advise to use a quantity of 1-2 maggots per square centimetre wound sur-



Figure 6. Maggots (Instar 3 larvae) after 4-5 days enclosed in a Biobag®

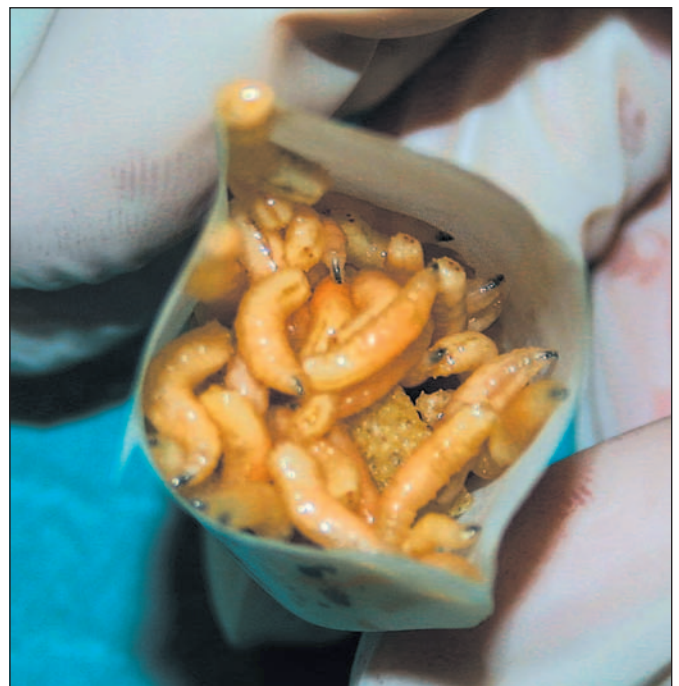

Figure 7. Biobag® after opening filled up with Instar 3 larvae after 4-5 days

face<sup>25</sup> for 3-4 days consecutively after which the bags containing maggots should be replaced in combination with a lavage of the wound.<sup>24</sup> Furthermore, it is necessary to flush the wound daily as many times as needed with a physiological saline solution in order to keep the surface wet. It has, however, to be borne in mind that excessive flushing could drown the larvae. Additionally, it is advised to change the covering gauze bandage daily to prevent odour and avoid the dressing to be filled with wound fluid and which could drown the larvae.

Sometimes, there are concerns about the patient's reticence to the utilization of MDT, but many reports show that patient acceptability is high<sup>26</sup>, and our observations also demonstrate that MDT is highly acceptable. Information on the procedure in form of handouts and posters at the ward wall has shown to increase the acceptance of both patients and their relatives.

### CONTRA-INDICATIONS AND FACTORS INFLUENCING MDT

Indication	Efficacy
<ul style="list-style-type: none"> <li>Wound debridement<sup>1,2</sup></li> <li>Ulcers<sup>2,3</sup></li> </ul>	+ +/-*
<ul style="list-style-type: none"> <li>Non-healing traumatic wounds<sup>4</sup></li> <li>Burn wounds</li> <li>Post surgical wounds</li> </ul>	+ +/- +/-
<ul style="list-style-type: none"> <li>Osteomyelitis<sup>4-6</sup></li> </ul>	+
<ul style="list-style-type: none"> <li>Gram-negative infected wounds<sup>7</sup></li> </ul>	-

**Table 1. Overview of (contra-) indications for MDT and side effects.**  
 +: High success rates in literature. +/-: Successful effects are reported, but there are inconsistent results or few studies. -: Probably, MDT is not effective.  
 \* Many reports describe the successful results of MDT in ulcer treatment, however Dumville et al.2 did not show a faster wound healing compared to hydrogel application, but MDT did provide an effective debridement.  
 1. Sherman RA. Wound Repair Regen. 2002;10:208-214. 2. Dumville JC et al. BMJ. 2009;338:b773. 3. Tantawi TI et al. J Wound Care. 2007;16:379-383. 4. Jukema GN et al. Zentralbl Chir. 2006;131:s75-78. 5. Baer WS. J Bone Joint Surg. 1931;13:438-475. 6. Galeano M et al. Plast Reconstr Surg. 2001;108:2178-2179. 7. Steenvoorde P et al. J Tissue Viability. 2004;14:97-101.

MDT is not indicated when there are open wounds in the abdominal cavity, because of the risk of organ lesions. Other contra-indications are *pyoderma gangrenosum* in patients with immunosuppressive therapy and septic arthritis.<sup>27-28</sup> Caution is advised when treating wounds near to large arteria and veins. MDT seems to be less effective in older patients suffering from chronic limb ischaemia.<sup>28</sup> It is unclear whether the effectiveness of MDT is influenced by patient characteristics, such as gender, obesity, smoking behavior or the presence of diabetes mellitus, because there are no data of randomized controlled trails available.

### SIDE EFFECTS

There are no severe side effects reported for MDT. Sometimes, a tickling feeling due to the crawling maggots is noted; however, after using the captured method, there are less complaints about this sensation. Exceptional cases, e.g. from patients with leg ulcers, who are suffering from ischaemic disease, report increased pain by MDT.<sup>28</sup> The origin of reported pain during maggot application is not known, since the wound heal-

ing effect of maggots is not related to their direct crawling action on the wound surface. In our daily clinical practice we cannot observe a difference in wound healing if MDT is used in the free range mode compared with the captured technique, with the possible exception of undermined complicated cavity wounds. An ancient article describes the development of transient pyrexia in some patients with chronic wounds and gross lymphatic changes.<sup>29</sup> In one case, a bleeding occurred during MDT in an arterious-venous ulcer but it is unclear whether the bleeding was related to MDT or not.<sup>30</sup> No allergic reactions were noted. The maggots used in MDT are *Lucilia sericata* larvae and cannot cause myiasis in humans, because they limit their actions to the necrotic wound and spare the healthy tissue. In our own clinical practice since 1993, we have never seen any severe side effects or severe adverse events related to MDT.

### Underlying mechanisms of action of MDT

In these times of increasing antibiotic resistance, it is important to search for and investigate (new) treatment methods to treat infections. MDT is very successful in curing infected wounds and therefore it is important to elucidate the underlying mode of action. MDT seems to have a multifactorial working mechanism that explains the efficacy of the therapy. Maggots seem to do their work in at least three areas, i.e. debridement, stimulation of wound healing by producing granulation tissue and disinfection.

### DEBRIDEMENT AND STIMULATION OF WOUND HEALING

Wound debridement is essential for the process of wound healing. Debridement is defined as the removal of necrotic and infected tissue and foreign material from and around a wound surface and it can be derived by mechanical (surgical), chemical or autolytic methods.<sup>31-32</sup> It is suggested that maggots debride the wound bed by mechanical and chemical techniques.<sup>33-34</sup> Mechanical debridement is performed by the specific mandibles or "mouthhooks" of the maggots and their rough body which both scratch the necrotic tissue. Furthermore, maggots produce excretions and secretions (ES) that possess proteolytic enzymes that can dissolve the dead and/or infected matrix on the wound bed.<sup>34</sup> However the long-standing hypothesis was that the mechanical debridement was one of the mechanisms responsible for the effectiveness of MDT, but current studies do not support this hypothesis. Instead, they show more evidence for the chemical mechanisms underlying to its success.<sup>35</sup>

We obtain maggot excretions and secretions by incubating sterile larvae in a saline solution in sterile tubes for one hour at 35°C in darkness.<sup>25</sup> After incubation, ES between the maggots are removed by pipette. We measure the protein concentration of ES, which is normally within a range between 1500 and 2000 µg/mL, and determine their acidity, which is normally pH 8, to standardize the collected pools. It is known that ES contain allantoin, sulfhydryl radicals, calcium, cysteine, glutathione, embryonic growth stimulating substance, growth stimulating factors for fibroblasts, carboxypeptidases A and B, leucine aminopeptidase, collagenase and serine proteases (trypsin-like and chymotrypsin-like enzymes, metalloproteinase and aspartyl proteinase).<sup>36</sup> Reports from *in vitro* studies suggest that wound debridement treatment with maggot ES alone could replace the current therapy with live maggots.<sup>13,35</sup> A recent *in vivo* study possibly supports the theory that the direct mechanical action of free-range maggots is limited. In this research, larval therapy with free-range maggots and maggots in Biobags® was compared with hydrogel application

→

→ and showed faster debridement with the maggots.<sup>37</sup> Although the larvae in Biobags needed 28 days to debride and free-range maggots only 14 days, both therapies were very effective in debridement compared with hydrogel which cleaned the wounds in 72 days. So, ES have an important role to play in wound debridement.

*In vitro* studies show that larval ES, probably the chymotrypsin-like and trypsin-like enzymes, are involved in the remodelling of extracellular matrix components.<sup>38</sup> They modify fibroblast adhesion and spreading across the extracellular matrix protein surfaces, while keeping cells viable. ES also have a motogenic influence on keratinocytes.<sup>34</sup> These effects of ES may stimulate tissue formation in the wound area.

## DISINFECTION

One of the leading hypotheses in the literature concerning the mode of action of maggots in the area of disinfection is that they appear to possess antibacterial properties. Several published studies suggest evidence of the presence of antibacterial effects of maggots and/or their secretions/excretions (ES) as an explanation for the success observed in daily clinical practice. However, these studies show different results. For example, Kerridge *et al.* performed a zone of inhibition assay showing antibacterial activity of native ES against gram-positive bacteria<sup>39</sup>, whereas Bexfield *et al.* using a similar method and found no antibacterial activity.<sup>40</sup> In one of our previous studies, we reinvestigated the susceptibility of strains of six bacterial species, which are regularly found in infected wounds, to live maggots and/or their ES to find additional proof supporting direct antibacterial activity.<sup>41</sup> However, we have not found any direct antibacterial activity, neither of the live maggots, nor of the ES. Because the former studies describe contradictory results, the mechanisms that are responsible for disinfection still remain uncertain.

In our own clinical practice, faster healing of wounds by treatment of MDT in combination with antibiotics has been observed. Based on these clinical observations and following our research on the antibacterial activity of ES, we hypothesized that maggot ES enhance the antibacterial activity of antibiotics and investigated the interaction between maggot ES and various antibiotic agents. Therefore, we performed an *in vitro* study including nine different combinations of antibiotics in combination with ES against six different bacterial strains, isolated from wounds present in our patients admitted to the department of trauma surgery in our institution.<sup>42</sup> A synergism between gentamycin and ES against *Staphylococcus aureus* and *Enterobacter cloacae* and between flucloxacillin and ES against *Staphylococcus aureus* was found. The enhanced antimicrobial activity of gentamycin in the presence of ES could be of direct importance in clinical practice, because it could permit the use of lower doses of gentamycin in patients with infections. A low concentration of gentamycin is already bactericidal in the presence of maggot ES and could therefore provide better patient security by reducing the risks of severe gentamycin-related side effects, such as nephrotoxicity and hearing loss.

Although maggot ES do not directly destroy free-living bacteria, they do have an effect on sessile bacteria.<sup>25,43</sup> Sessile bacteria are embedded in a self-producing polymer matrix as a structured bacterial population and are attached to inert or living substances, e.g. wound surfaces or prosthetic materials. The process of embedding is called biofilm formation. The biofilm matrix prevents the bacteria from being killed by antibiotics.<sup>44</sup> Therefore, biofilm-associated infections are hard to combat

and they are becoming more frequent in these times of rising antibiotic resistance, especially in device-related infections that are always caused by biofilms. Maggot ES can prevent, inhibit and break down biofilms of various bacteria on commonly used prosthetic materials and thus, may provide a new treatment of biofilm-associated infections of orthopaedic biomaterials.<sup>25</sup> The fact that ES can reduce biofilms can partially explain wound debridement by MDT. A biofilm matrix can be recognized as a viscous layer on a wound surface and is foreign material that has to be debrided before the healing can progress.

Despite the finding of the biofilm-reducing properties of ES, which explains, in our opinion, more the debriding than the disinfecting effect of MDT, no other direct influence of the larvae on disinfection of the wounds has been found, although the therapy is highly effective.<sup>16</sup> We therefore hypothesize that there is an indirect antibacterial mechanism in which the immune system is involved. In clinical practice, no allergic side effects were ever described and although larvae are foreign creatures, they are able to colonize our human tissue. In a previous study, we showed that maggot ES inhibit multiple neutrophil pro-inflammatory responses.<sup>45</sup> Currently, we are investigating other immune-related effects to maggots.

## Conclusions

The maggots of *Lucilia sericata* are especially indicated for wounds that need debridement.<sup>37</sup> MDT has been known to be an effective therapy from ancient times and no severe side effects have been reported in the literature. Since MDT was reintroduced in the last decade of the last century, especially in European countries, this modality of treatment of infected (surgical) wounds is attracting more attention. Today, two modes of application are available, the free range and captured method. Both methods of application seem to be safe and serious adverse events during treatment have not been reported in the literature. No differences between the two methods in terms of efficacy in wound healing have been observed to date. Part of the underlying mechanism of action of MDT can be explained by debridement of the wound bed, which includes biofilm reduction and the effect on extracellular matrix components. Maggots and/or ES do not possess direct antibacterial properties. However, there is an immune-related effect of maggot ES, which results in the reduction of the pro-inflammatory response.

## Discussion and future prospects

Although MDT is successful, more research is needed to clarify the exact underlying mechanism of action. The immunological and chemical effects of the excretions and secretions that were produced by maggots seem to play an important role in the wound healing process. Future studies are needed in order to investigate the composition of maggot ES and determine the effective substances that are responsible for the debridement, including the remodelling effect on the extracellular matrix components and the reduction of biofilm formation. These substances could contribute to the development of a new treatment for wound debridement and/or for biofilm reduction on infected biomaterials. Furthermore, we could observe interaction between certain antibiotic agents and ES reducing bacterial growth. To acquire more knowledge about the working mechanisms of MDT one of our current topics of interest is focused on the immune-related effects of maggots on wound healing. Together with fundamental basic research work, randomized controlled multicenter clinical trials are needed to come to derive evidence-based status for maggot debridement therapy, which seems to be in effective clinical practice. ■

## References

1. Sherman RA, Hall MJR, Thomas S. Medicinal maggots: an ancient remedy for some contemporary afflictions. *Annu Rev Entomol*. 2000; 45: 55-81.
2. Steenvoorde P, Jukema GN. The antimicrobial activity of maggots: in-vivo results. *J Tissue Viability*. 2004; 14: 97-101.
3. Fleischmann W, Grassberger M, Sherman RA. Maggot therapy. *A Handbook of Maggot-Assisted Wound Healing*. New York; Thieme; 2003.
4. Larrey, Baron DJ. Observations on wounds, and their complications by erysipelas, gangrene and tetanus etc. Translated from the French by EF Rivinus, Philadelphia Key, Mielke and Biddele. 1832; p.34.
5. Baer WS. The treatment of chronic osteomyelitis with the maggot (larvae of the blowfly). *J Bone Joint Surg*. 1931; 13: 438-475.
6. Chain E, Florey HW, Gardner AD, Heatley HG, Jenning MA, Orr-Ewing J *et al*. Penicillin as a chemotherapeutic agent. *Lancet* 1940; 2: 226-228.
7. Wainwright M. *Miracle Cure: The Story of Penicillin and the Golden Age of Antibiotics*. Oxford: Basil Blackwell; 1990.
8. Sherman RA, Pechter EA. Maggot therapy: a review of the therapeutic applications of fly larvae in human medicine, especially for treating osteomyelitis. *Med Vet Entomol*. 1988; 2: 225-230.
9. Steenvoorde P, Jukema GN. The antimicrobial activity of maggots: in-vivo results. *J Tissue Viability*. 2004; 14: 97-101.
10. Sherman RA, Hall MJR, Thomas S. Medicinal maggots: an ancient remedy for some contemporary afflictions. *Annu Rev Entomol*. 2000; 45: 55-81.
11. Jukema GN, Menon AG, Bernards AT, Steenvoorde P, Taheri Rastegar A, Van Dissel JT. Amputation-sparing treatment by nature: 'surgical' maggots revisited. *Clin Infect Dis*. 2002; 35: 1566-1571.
12. [www.fda.gov/ohrms/dockets/ac/05/briefing/2005-4168b1\\_Classification%20Memo.pdf-08-24-2005](http://www.fda.gov/ohrms/dockets/ac/05/briefing/2005-4168b1_Classification%20Memo.pdf-08-24-2005)
13. Chan DC, Fong DH, Leung JY, Patil NG, Leung GK. Maggot debridement therapy in chronic wound care. *Hong Kong Med J*. 2007; 13(5):382-386.
14. Tanyuksel M, Araz E, Dundar K, Uzun G, Gumus T, Alten B *et al*. Maggot debridement therapy in the treatment of chronic wounds in a military hospital setup in Turkey. *Dermatology*. 2005; 210: 115-118.
15. Brin YS, Mumcuoglu KY, Massarwe S, Wigelman M, Gross E, Nyska M. Chronic foot ulcer management using maggot debridement and topical negative pressure therapy. *J Wound Care*. 2007; 16(3):111-113.
16. Wolff H, Hansson C. Larval therapy - an effective method for ulcer debridement. *Clin Exp Dermatol*. 2003; 28(2):134-137.
17. Fadaak H. Maggot debridement therapy. *Burns*. 2003; 29(1):96.
18. Sherman RA, Shapiro CE, Yang RM. Maggot therapy for problematic wounds: uncommon and off-label applications. *Adv Skin Wound Care*. 2007; 20(11):602-610.
19. Brüggman D, Tinneberg HR, Zygmunt MT. Maggot therapy in gynecology. *Zentralbl Gynakol*. 2006; 128(5):261-265.
20. Arribillaga J, Rodríguez J, Oviedo M. Preliminary evaluation of maggot (Diptera: Calliphoridae) therapy as a potential treatment for leishmaniasis ulcers. *Biomedica*. 2008; 28(2):305-310.
21. Horn KL, Cobb AH, Gates GA. Maggot therapy for sub-acute mastoiditis. *Arch Otolaryngol* 1976; 102: 377-379.
22. Steenvoorde P, van Doorn LP, Jacobi CE, Oskam J. Maggot debridement therapy in the palliative setting. *Am J Hosp Palliat Care*. 2007; 24(4):308-310.
23. Grassberger M, Fleischmann W. The biobag - a new device for the application of medicinal maggots. *Dermatology*. 2002; 204(4):306.
24. Blake FA, Abromeit N, Bubenheim M, Li L, Schmelzle R. The biosurgical wound debridement: experimental investigation of efficiency and practicability. *Wound Repair Regen*. 2008; 16(3):466.
25. Cazander G, van Veen KEB, Bouwman LH, Bernards AT, Jukema GN. The influence of maggot excretions on PAO1 biofilm formation on different biomaterials. *Clin Orthop Relat Res*. 2009; 467(2):536-545.
26. Petherick ES, O'Meara S, Spilsbury K, Iglesias CP, Nelson EA, Torgerson DJ. Patient acceptability of larval therapy for leg ulcer treatment: a randomized survey to inform the sample size calculation of a randomised trial. *BMC Med Res Methodol*. 2006; 6: 43.
27. Renner R, Treudler R, Simon JC. Maggots do not survive in *pyoderma gangrenosum*. *Dermatology*. 2008; 217(3):241-243.
28. Steenvoorde P, Jacobi CE, Van Doorn L, Oskam J. Maggot debridement therapy of infected ulcers: patient and wound factors influencing outcome - a study on 101 patients with 117 wounds. *Ann R Coll Surg Engl*. 2007; 89(6):596-602.
29. Buchman J, Blair JE. Maggots and their use in the treatment of chronic osteomyelitis. *Surg Gynecol Obstet*. 1932; 55: 177-190.
30. Steenvoorde P, van Doorn LP. Maggot debridement therapy: serious bleeding can occur: report of a case. *J Wound Ostomy Continence Nurs*. 2008; 35(4):412-414.
31. Bale S. A guide to wound debridement. *J Wound Care*. 1997; 6(4):179-182.
32. Gottrup, F. Wound Debridement. In: Shukla VK, Mani R, Teot L, Pradhan S, eds. *Management of Wound Healing*. Jaypee, New Delhi. 2007, pp. 107-119.
33. Mumcuoglu KY, Miller J, Mumcuoglu M, Friger M, Tarshis M. Destruction of bacteria in the digestive tract of the maggot of *Lucilia sericata* (Diptera: Calliphoridae). *J Med Entomol*. 2001; 38(2):161-6.
34. Chambers L, Woodrow S, Brown AP, Harris PD, Phillips D, Hall M *et al*. Degradation of extracellular matrix components by defined proteinases from the greenbottle larva *Lucilia sericata* used for the clinical debridement of non-healing wounds. *Br J Dermatol*. 2003; 148: 14-23.
35. Smith AG, Powis RA, Pritchard DI, Britland ST. Greenbottle (*Lucilia sericata*) larval secretions delivered from a prototype hydrogel wound dressing accelerate the closure of model wounds. *Biotechnol Prog*. 2006; 22(6):1690-1696.
36. Gupta A. A review of the use of maggots in wound therapy. *Ann Plast Surg*. 2008; 60(2):224-227.
37. Dumville JC, Worthy G, Bland JM, Cullum N, Dowson C, Iglesias C *et al*. Larval therapy for leg ulcers (VenUS II): randomised controlled trial. *BMJ*. 2009; 338: b773.
38. Horobin AJ, Shakesheff KM, Woodrow S, Robinson C, Pritchard DI. Maggots and wound healing: an investigation of the effects of secretions from *Lucilia sericata* larvae upon interactions between human dermal fibroblasts and extracellular matrix components. *Br J Dermatol*. 2003; 148(5):923-33.
39. Kerridge A, Lappin-Scott H, Stevens JR. Antibacterial properties of larval secretions of the *Lucilia sericata*. *Med Vet Entomol*. 2005; 19(3):333-7.
40. Bexfield A, Nigam Y, Thomas S, Ratcliffe NA. Detection and partial characterisation of two antibacterial factors from the excretions/secretions of the medicinal maggot *Lucilia sericata* and their activity against methicillin-resistant *Staphylococcus aureus* (MRSA). *Microbes Infect*. 2004; 6(14):1297-304.
41. Cazander G, van Veen KEB, Bernards AT, Jukema GN. Do maggots have an influence on bacterial growth? A study on the susceptibility of strains of six different bacterial species to maggots of *Lucilia sericata* and their excretions/secretions. *J Tissue Viability*. 2009 (in press).
42. Cazander G, Pawiroredjo JS, Vandembroucke-Grauls CMJE, Schreurs MWJ, Jukema GN. Maggot excretions enhance the antimicrobial effect of antibiotics (*manuscript submitted*).
43. Van der Plas MJ, Jukema GN, Wai SW, Dogterom-Ballering HC, Lagendijk EL, van Gulpen C *et al*. Maggot excretions/secretions are differentially effective against biofilm of *Staphylococcus aureus* and *Pseudomonas aeruginosa*. *J Antimicrob Chemother*. 2008; 61: 117-122.
44. Costerton JW. Biofilm theory can guide the treatment of device-related orthopaedic infections. *Clin Orthop Relat Res*. 2005; 437: 7-11.
45. Van der Plas MJ, van der Does AM, Baldry M, Dogterom-Ballering HC, van Gulpen C, van Dissel JT *et al*. Maggot excretions/secretions inhibit multiple neutrophil pro-inflammatory responses. *Microbes Infect*. 2007; 9(4):507-514.