The use of an oxygenating hydrogel dressing in VLU

Hydrogel dressings have proven their usefulness in the treatment of chronic wounds. Oxyzyme™, a new novel hydrogel dressing containing an active enzyme system was evaluated in the treatment of patients with chronic venous leg ulcers. The clinical benefits observed included pain management, exudate management and the creation of a healing environment. It is hypothesised that the healing environment is optimised through oxygenation of the wound. The case studies presented here demonstrate the usefulness of this dressing.

Nicky Ivins, Wendy Simmonds, Anna Turner, Keith Harding

KEY WORDS
Hydrogel dressing
Oxygenation
Venous leg ulcers
Advanced dressing

The treatment of chronic wounds represents a major cost to society and is a frequently encountered problem in older patients and those confined to bed (Harding et al, 2002). Chronic wounds commonly arise from trauma or pathological insult and can have a profound effect on the patient's quality of life (Grey et al, 2006a).

A chronic wound is, by definition, one that is difficult to heal (Grey et al, 2006b). The majority of such wounds occur as pressure ulcers or dermal ulcers caused by vascular disorders of the extremities (arterial ischaemia or venous stasis disease). A common causative factor is interrupted or inadequate blood flow to the affected area, which leads to hypoxia and tissue death (Enoch et al, 2006).

Nicky Ivins is Clinical Trials Coordinator, Wendy Simmonds and Anna Turner are Research Nurses, and Professor Keith Harding is Professor of Rehabilitative Medicine, Wound Healing Research Unit, Cardiff University, Cardiff, Wales

Effective management of chronic wounds must:

- Correct the underlying cause
- Promote healing
- Resolve patient discomfort (Grey et al, 2006c).

The management of chronic wounds typically involves a multidisciplinary approach (Gottrup, 2003) to:

- Provide physical protection of the compromised tissue
- Maintain an appropriate local environment to help promote healing, such as topical antisepsis, moisture retention and exposure to oxygen
- Prescribe the use of topical or systemic antimicrobial agents when infection arises or exists
- Provide concomitant medication to help reduce inflammation and any associated pain.

Advanced wound care dressings have proven over the past 20 years that they offer significant benefits in the management of venous leg ulcers (Queen et al, 2004). One category of dressing which has never realised its potential is the sheet hydrogel (Harding et al, 2000). This category has been limited by its performance in the area of exudate management and infection control (Jones et al, 2006). However, the new generation of advanced hydrogels have much improved exudate management.

The role of oxygen in wound healing

Oxygen's key role in the healing of wounds is well understood (Ueno et al, 2006). Wound healing is an energy-demanding process and oxygen is needed to support the respiration essential to release the required energy (Trabold et al, 2003; Hunt et al, 2004). Its role in healing is multifaceted an d it is needed for:

- Energy metabolism: important for the cellular processes of repair
- Collagen synthesis: important for tissue regeneration
- Neovascularization: important for tissue regeneration
- Polymorphonuclear cell function: important for the first-line defence against micro-organisms
- Antimicrobial action: many of the pathogenic and malodorous bacteria found in wounds are obligate anaerobes which will be killed in an oxygenated environment. Some antibiotics need the presence of oxygen to exert their antimicrobial effects.

Studies using hyperbaric oxygen have shown positive effects on wound healing (Hopf et al, 2001; Gordillo and Sen, 2003). These studies and other research findings support the important role of oxygen in wound repair

(Knighton et al, 1986; Allen et al, 1997; Hopf et al, 1997; Sheikh et al, 2000; Kalliainen et al, 2003).

The use of oxygen delivery devices, whether topical or systemic, remains controversial but there is a growing body of evidence. There is still no formal consensus on whether topically applied gaseous oxygen accelerates healing, despite the underlying evidence of oxygen's central role. To resolve the issue, it may be necessary to pay attention to the mode of oxygen application, since the application of gaseous oxygen to wounds is much less effective than applying dissolved oxygen (Gottrup, 2004; Tandara and Mustoe, 2004; Cronje, 2005; Londahl et al, 2006).

The Oxyzyme™ wound dressing

The enzyme-activated hydrogel dressing system (Oxyzyme™ Sterile Wound Dressing with Iodine; Insense Ltd, UK) is a new type of dressing that interacts with the wound to promote healing through wound bed preparation enhanced by the restoration of oxygen balance.

It is an occlusive, sterile, single use hydrogel wound dressing for the local management of dry to medium exudating, non-infected, superficial wounds. It can be used on more highly exudating wounds in conjunction with a secondary absorbent covering. Its advanced hydrogel format is designed to provide a soothing, moist environment conducive to healing and autolytic debridement. The dressing is a two component system where a wound contact hydrogel is brought into contact with a smaller enzyme containing hydrogel. This combining of the two layers activates the system.

Mechanism of action

The Oxyzyme™ dressing uses a strategy similar to one of the most powerful leukocyte biochemical strategies; the respiratory burst.

Contained within the dressing is an oxidase enzyme, and a halide, iodide. When Oxyzyme™ is removed from its air-tight packaging and assembled on the wound, the oxidase enzyme within the top layer is activated upon contact with oxygen in the air and by the new contact made between the two layers of the dressing.

Just as in leukocytes, the oxidase enzyme reacts with oxygen in the air to generate a steady flux of hydrogen peroxide within the dressing. When it reaches the wound-facing surface, the hydrogen peroxide is instantly converted, through its interaction with the iodine component of the dressing, into dissolved oxygen before it can leave the dressing. In this way, the hydrogen peroxide is uniquely used as an oxygen shuttle, transporting oxygen to the wound environment. In addition to the potential metabolic benefits of the oxygen, it also helps to inhibit anaerobic bacteria.

This effect is further enhanced by the incorporation of a very low level of iodide (less than 0.04% w/w) within the hydrogel. The hydrogen peroxide oxidises the iodide to produce molecular iodine. The iodine helps creates an environment hostile to bacteria at the wound interface (Thorn et al, 2006).

The dressing is designed to encourage healing by providing physical protection, moisture retention and fluid balance, localised oxygenation and surface microbicidal action.

Method

A non-comparative, 6-week clinical study was undertaken with the Oxyzyme™ Sterile Wound Dressing with Iodine (10x10cm) for the treatment of venous leg ulcers, in accordance with the RCN (RCN, 1998) and SIGN guidelines (SIGN, 1998), with concomitant use of graduated high compression therapy. The primary objectives were to evaluate the safety and performance of the dressing. Wound healing was measured against a number of standard characteristics of chronic wounds:

- The extent of tissue involvement
  - Area (length x width) cm^2 (measured by acetate tracing).
- Wound surface
  - Type of tissue (necrotic, slough, granulation)
  - Exudate amount (scant, small, moderate, large)
  - Exudate type (serous, sero-sanguinous, purulent).
- Wound malodour
- Changes in the condition of the surrounding skin
- Rate of healing (number of days)
- Patient acceptability (comfort/pain scores).

The secondary objective was to establish the general acceptability of the dressings in routine use, using patient and nurse scoring systems.

Four case studies are presented here, from a larger 31 patient multi-centre study, the results of which are yet to be published.

Case study 1

A 43-year-old male with type 2 diabetes and a 3-month history of venous leg ulceration was being treated with voltarol, co-codamol and simvastatin. As a keen rugby player with a young family, his wound caused inconvenience and limited his daily activities. The patient presented with a granulating ulcer on his right lateral gaiter area (*Figure 1a*). He was experiencing moderate pain and the wound was producing moderate levels of exudate. The wound measured 1.2cm^2 and appeared to be healthy and granulating without the presence of odour. The surrounding skin was odematous and dry and flaky, requiring treatment with an emollient.

A 10x10cm Oxyzme™ dressing was applied to the wound; no secondary dressing was required. The dressing was changed twice weekly throughout the study. By day 14, the pain and exudate levels had reduced from moderate to mild and the wound had reduced in size to 0.5cm^2. Oedema was reduced in the surrounding skin, although it remained dry and flaky. The wound bed remained healthy and granulating, without the presence of any odour. After a further 14 days, the ulcer healed (*Figure 1b*) and remained healed at the 4-week follow-up. The patient

Figure 1a. Wound on entry to study.

Figure 1b. Wound healed by day 28.

commented that the dressing had been comfortable and soothing, and was pleased that the ulcer had healed.

Case study 2

An 86-year-old female with high cholesterol that was being treated with crestor, presented with a 3-year-old over-granulating ulcer on her right lateral malleolus. The wound was resulting in mild intermittent pain and producing light to moderate exudate (*Figure 2a*). Previous treatment had included compression and topical antimicrobial dressings, with little effect on the ulcer size.

At initiation of treatment with Oxyzyme™, the ulcer measured 1.6cm^2, and the wound bed was granulating with no slough present. The surrounding skin was dry and flaky and required emollients. Dressing changes were made on average every 4 to 5 days. Within 7 days, the ulcer had reduced in size and the pain had lessened from moderate to mild. By day 28 the ulcer had reduced in size by 90%. At day 35, the ulcer healed (*Figure 2b*) and remained healed at the 4-week follow-up.

The patient was satisfied with the performance of the dressing and the

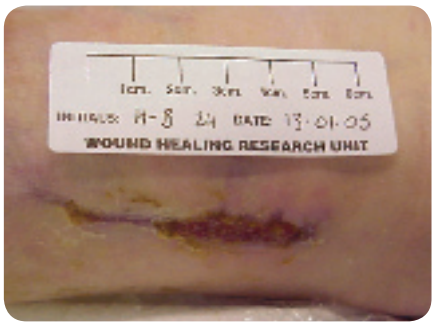

Figure 2a. Wound upon entry to study.

Figure 2b. Healed ulcer at day 35.

healing of the ulcer as demonstrated with high pain and comfort scores.

Case study 3

A 67-year-old female with angina, arthritis and an ABPI of 1.09 presented with a 7-month-old, non-healing, shallow, venous leg ulcer that measured 1.2 x 0.9cm (*Figure 3a*). The exudate was light but the patient was in continuous pain. She was receiving ismo, co-codamol, aspirin and premarin. The wound bed had granulating tissue present, with evidence of slough in the base of the wound. The surrounding skin was dry and flaky with evidence of small areas of eczema which was treated with emollients. A 10x10cm Oxyzyme™ dressing was applied over the ulcer, which measured 0.8cm^2. Until day 14, the dressing was changed three times a week, after which time it was changed twice weekly. At day 7, the wound showed an increase in size, measuring 1.3cm^2 and the patient experienced an increase in eczema which was treated with steroid ointment. Elocon was prescribed and the pain continued. By day 14, the wound had decreased in size to 0.8cm^2 and the eczema had improved. The pain decreased to intermittent and settled with analgesia. The wound had healed

Figure 3a. Wound upon entry to study.

Figure 3b. Wound had healed by day 28.

by day 28 (*Figure 3b*). The outcomes of healing and pain reduction provided high satisfaction for the patient.

Case study 4

A 60-year-old female with hypertension, an under-active thyroid, type 1 diabetes, and an ABPI of 1.0, presented with an 8-week-old, shallow venous leg ulcer that measured 1.5 x 0.8cm (*Figure 4a*). She was being treated with insulin, frusemide and other medications for her other disease conditions. On entry into the study, the wound bed was granulating and sloughy with light exudate. The patient experienced intermittent moderate pain which

Figure 4a. Wound upon entry to study.

Figure 4b. Healed wound at day 35.

was tolerated with analgesia. The surrounding skin was erythematic, with dry and flaky skin and eczema present. The eczema was treated with Eumovate ointment and emollients. The Oxyzyme™ dressing was changed twice weekly. No secondary dressing was required. By day 14 of treatment, the wound was granulating and had divided into 2 distinct wounds (0.8 x 0.2cm and 0.3 x 0.1cm). By day 35 the wound had healed (*Figure 4b*), and remained closed at the 4-week follow up. The patient was satisfied with the performance of the dressing and the healing of the ulcer as demonstrated with high pain and comfort scores.

Case study 5

A 51-year-old male presented with a small leg ulcer. He had suffered from recurrent leg ulceration following a road traffic accident 15 years ago. He was being treated with an antimicrobial dressing and high compression therapy, plus analgesia for general bone pain. He had no other underlying diseases. Following clinical assessment and an

Figure 5a. Wound upon entry in study.

Figure 5b. Healed wound at day 35.

ABPI of 1.2, a diagnosis of venous disease was made.

At entry to the study the wound was 1.1cm^2 and the wound bed had both granulation tissue and slough present (*Figure 5a*). On the day of initial treatment a 10cmx10cm Oxyzyme™ dressing was applied over the ulcer. No secondary dressing was required and the dressing was changed twice weekly. By day 7, following two dressing applications, the wound was clean and healthy with no slough. By day 35 the wound had healed (*Figure 5b*) and remained closed at the 4-week follow-up.

The patient consistently gave high pain and comfort scores indicating a high level of satisfaction with the performance of the dressing and the healing of the ulcer.

Discussion and conclusions

The novel Oxyzyme™ dressing was liked by patients and carers. There were no significant safety concerns and the dressing proved to be beneficial

This provides evidence that the Oxyzyme dressing can provide a wound environment conducive to healing by addressing the requirements of good wound bed preparation.

in the treatment of venous leg ulcers with all of the patients described in the case studies healing completely within the 6-week trial period. This provides evidence that the Oxyzyme dressing can provide a wound environment conducive to healing by addressing the requirements of good wound bed preparation. The results were surprising in that a number of recalcitrant wounds healed in the six week timeframe, even though they were small in size initially. Further studies are required to confirm the usefulness of this product in the treatment of venous leg ulcers and other chronic wounds. WUK

References

Allen DB, Maguire JJ, Mahdavian M (1997) Wound hypoxia and acidosis limit neutrophil bacterial killing mechanisms. *Arch Surg* 132(9): 991–6

Chikungwa MT, Jonsson K (2002) The need for peri-operative supplemental oxygen. *Cent Afr J Med* 48(5–6): 72–4

Cronje FJ (2005) Oxygen therapy and wound healing – topical oxygen is not hyperbaric oxygen therapy. *S Afr Med J* 95(11): 840

Enoch S, Grey JE, Harding KG (2006) Recent advances and emerging treatments. *Br Med J* 332(7547): 962–5

Key Points

- Oxygenation of the wound environment appears to influence healing.
- A novel hydrogel system oxygenates the wound environment.
- Five case histories demonstrate the value of the new advanced hydrogel dressing in the treatment of VLUs.

Grey JE, Harding KG, Enoch S (2006a) Pressure ulcers. *Br Med J* **332(7539)**: 472–5

Grey JE, Enoch S, Harding KG (2006b) Wound assessment. *Br Med J* **332(7536)**: 285–8

Grey JE, Harding KG, Enoch S (2006c) Venous and arterial leg ulcers. *Br Med J* **332(7537)**: 347–50

Gottrup F (2003) Organization of wound healing services: the Danish experience and the importance of surgery. *Wound Repair Regen* **11(6)**: 452–7

Gottrup F (2004) Oxygen in wound healing and infection. *World J Surg* **28(3)**: 312–5

Gordillo GM, Sen CK (2003) Revisiting the essential role of oxygen in wound healing. *Am J Surg* **186(3)**: 259–63

Harding KG, Jones V, Price P (2000) Topical treatment: which dressing to choose. *Diabetes Metab Res Rev* **16 Suppl 1**: S47–50

Harding KG, Morris HL, Patel GK (2002) Science, medicine and the future: healing chronic wounds. *Br Med J* **324(7330)**: 160–3

Hopf HW, Humphrey LM, Puzziferri N, West JM, Attinger CE, Hunt TK (2001) Adjuncts to preparing wounds for closure: hyperbaric oxygen, growth factors, skin substitutes, negative pressure wound therapy (vacuum-assisted closure). *Foot Ankle Clin* **6(4)**: 661–82

Hopf HW, Hunt TK, West JM, et al (1997) Wound tissue oxygen tension predicts the risk of wound infection in surgical patients. *Arch Surg* **132(9)**: 997–1004

Hunt TK, Ellison EC, Sen CK (2004) Oxygen: at the foundation of wound healing--introduction. *World J Surg* **28(3)**: 291–3

Jones V, Grey JE, Harding KG (2006) Wound dressings. *Br Med J* **332(7544)**: 777–80

Kalliainen LK, Gordillo GM, Schlanger R, Sen CK (2003) Topical oxygen as an adjunct to wound healing: a clinical case series. *Pathophysiology* **9(2)**: 81–7

Knighton DR, Halliday B, Hunt TK (1986) Oxygen as an antibiotic. A comparison of the effects of inspired oxygen concentration and antibiotic administration on in vivo bacterial clearance. *Arch Surg* **121(2)**: 191–5

Londahl M, Katzman P, Nilsson A, et al (2006) A prospective study: hyperbaric oxygen therapy in diabetics with chronic foot ulcers. *J Wound Care* **15(10)**: 457–9

RCN Clinical Practice Guidelines (1998) *The Management of Patients with Venous Leg Ulcers Improving Practice, Improving Care Series.* RCN, London

Sheikh AY, Gibson JJ, Rollins MD, Hopf HW, Hussain Z, Hunt TK (2000) Effect of hyperoxia on vascular endothelial growth factor levels in a wound model. *Arch Surg* **135(11)**: 1293–7

Tandara AA, Mustoe TA (2004) Oxygen in wound healing-more than a nutrient. *World J Surg* **28(3)**: 294–300. Epub 2004 Feb 17

Thorn RMS, Greenman J, Austin A (2006) An in vitro study of antimicrobial activity and efficacy of iodine-generating hydrogel dressings. *J Wound Care* **15(7)**: 305–10

Scottish Intercollegiate Guidelines Network (1998) *The Care of Patients with Chronic Leg Ulcer: A National Clinical Guideline.* SIGN Publications, Edinburgh: no. 26

Trabold O, Wagner S, Wicke C, et al (2003) Lactate and oxygen constitute a fundamental regulatory mechanism in wound healing. *Wound Repair Regen* **11(6)**: 504–9

Ueno C, Hunt TK, Hopf HW (2006) Using physiology to improve surgical wound outcomes. *Plast Reconstr Surg* **117(7 Suppl)**: 59S–71S

Queen D, Orsted H, Sanada H, Sussman G (2004) A dressing history. *Int Wound J* **1(1)**: 59–77