

NEW METHOD FOR HEALING OF LARGE ABDOMINAL WOUND USING SODIUM HYALURONATE-IODINE COMPLEX

Sobotka L., Maňák J., Vyroubal P., Šlemrová M., Mottl R., Adámková V., Bláha V.
Department of Metabolic Care and Gerontology Medical Faculty,
Charles University Hradec Králové, Czech Republic

Introduction

Wound dehiscence after surgical procedure is serious complication of surgical procedures. Especially when complicated by intestinal fistula the treatment is difficult. Hyaluronan-iodine (H-I) complex (Hyiodine®) was successfully used for treatment of sternal dehiscence pressure ulcers, and diabetic defects in our department. The aim of present study was to assess the effect of H-I complex on abdominal suture dehiscence healing.

Methods

Effect of Hyiodine® was assessed in 54 patients with abdominal wound dehiscence, 27 wounds were complicated by associated intestinal fistula.

The dressing was changed when necessary. Frequencies of H-I complex wound dressings exchanges were compared with these before usage of this complex.

The length of treatment and change in wound diameter were also measured. Wound pictures were taken by digital camera (Camedia – Olympus).

Results

Bandage immersed with Hyiodine® was changed once per 24 hours. However, before introduction this method the wound dressing had to be changed 5.4 ± 2.3 (mean \pm std) times per 24 hours.

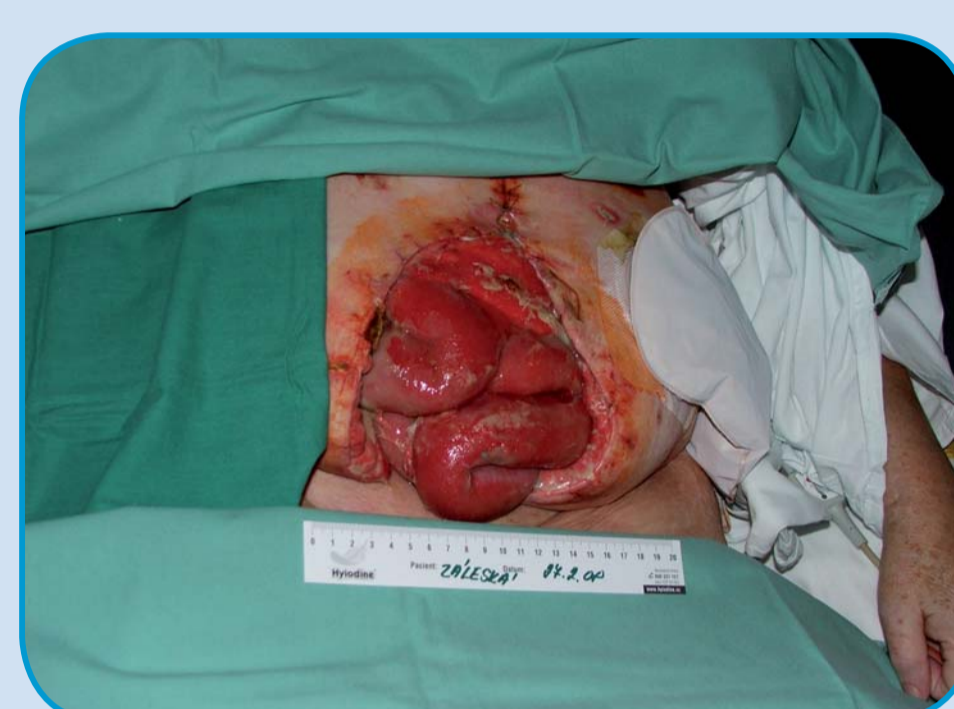
Hyiodine® dressings did not adhere to the wounds, and also no maceration was apparent on the skin surrounding the wounds. All wounds without intestinal fistula healed within 32.1 ± 21.3 days. Wounds complicated by intestinal fistula did not heal completely but decreased substantially their area within 48.5 ± 36.3 days. This enabled definitive surgical procedure or usage colostomy device and oral nutrition. No side effect of treatment or iodine sensitivity was apparent during the Hyiodine® treatment.

Conclusion

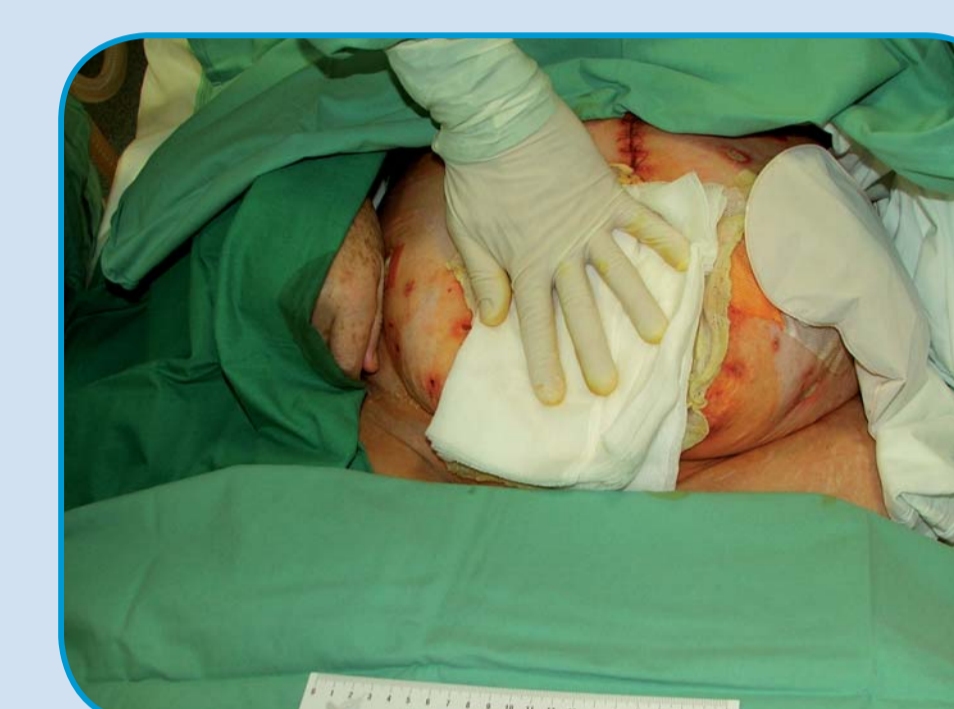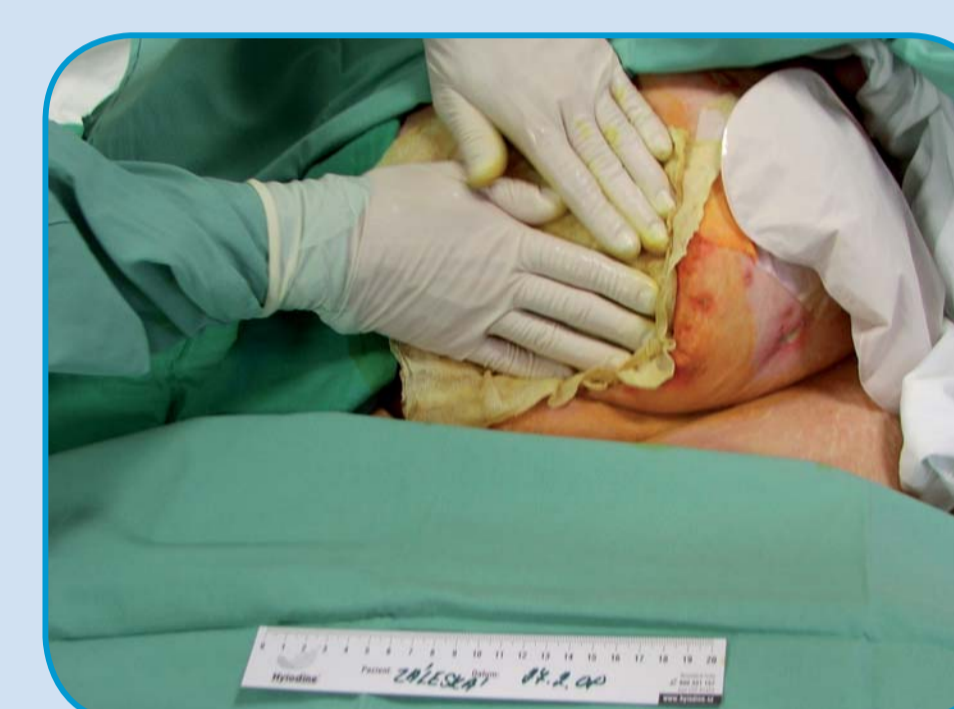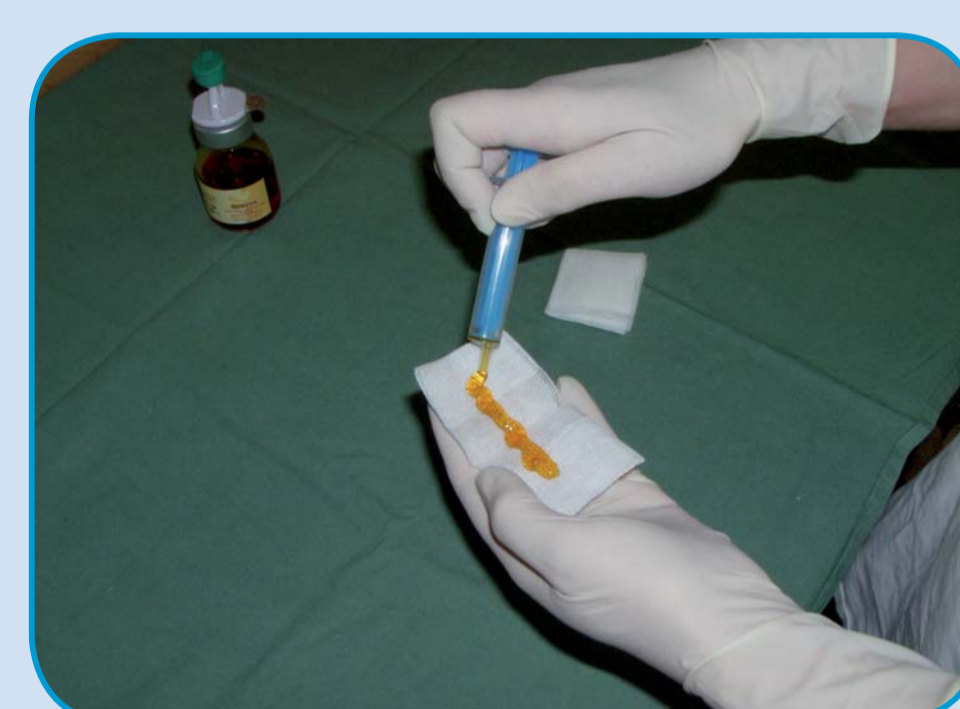The complex of pure hyaluronan with iodine was confirmed as useful tool for the treatment of abdominal catastrophes with large dehiscence. The positive effect of this treatment is probably related to fluid retention due to hyaluronan application, together with anti-microbial effect of iodine. However, effect of hyaluronan on immune cells activation and angiogenesis can also explain the favorable effect of Hyiodine.

This study was supported by grant MSM 0021620820 Czech Republic.

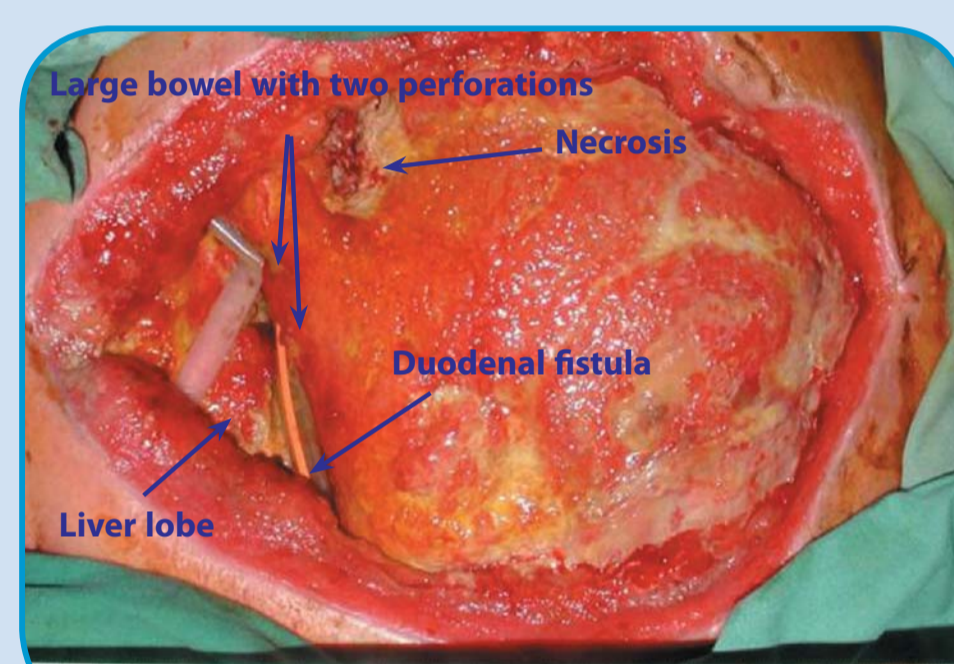
Presented at: EWMA 2008, May 14–16, 2008, Lisbon, Portugal



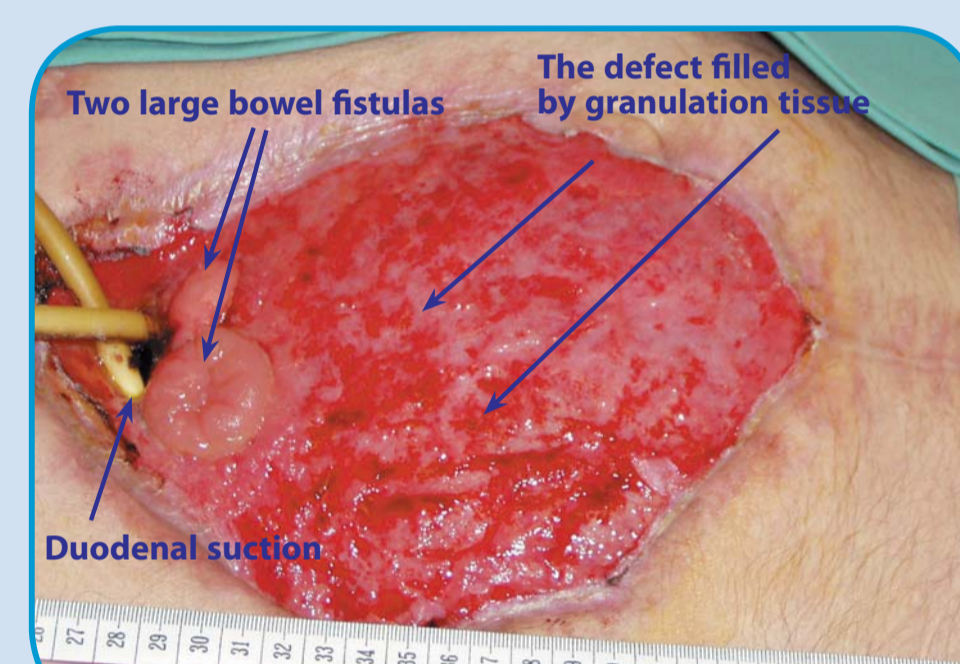
Sterile gauze immersed in Hyiodine® was put directly on/into the wound. Then several layers of dry gauze covered the wound. Potentially, skin adaptation was done using adhesive tape.



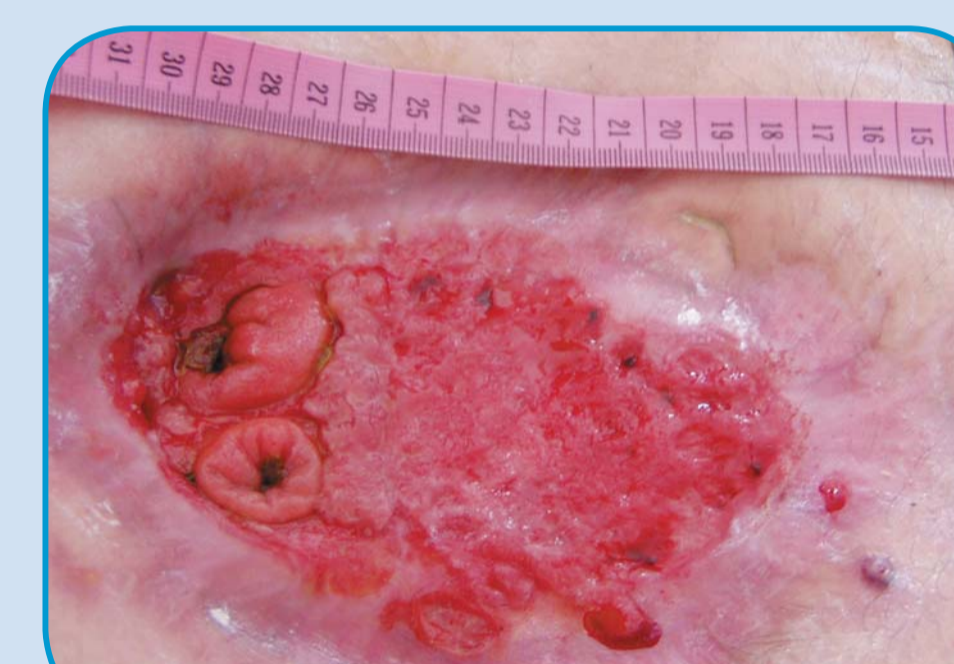
CASE 1



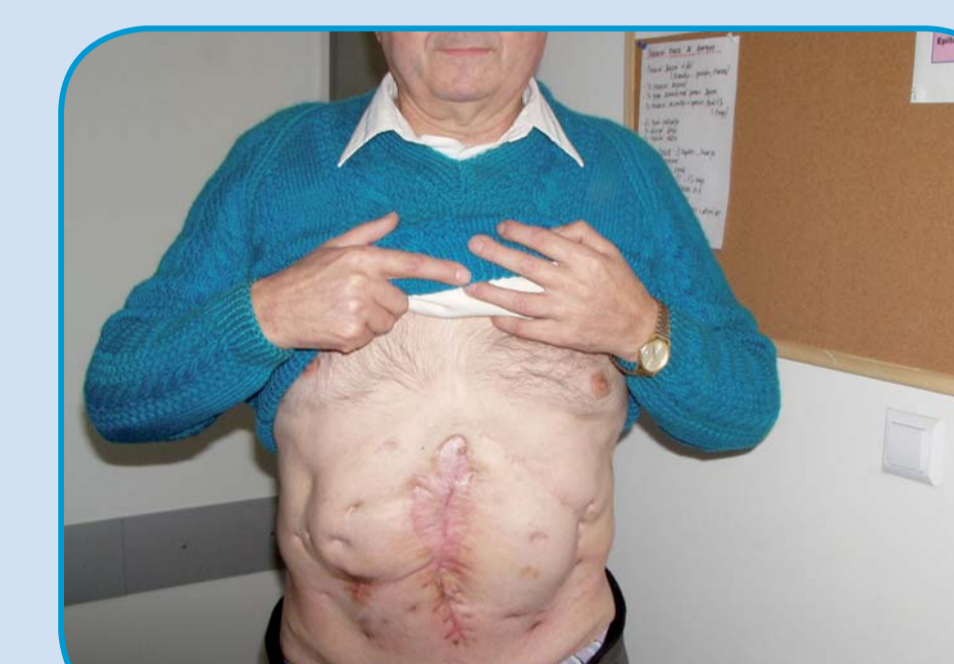Large wound dehiscence with multiple intestinal fistulas after multiple operations due to acute pancreatitis.



The wound after 10 weeks of hyaluronan-iodine complex treatment.

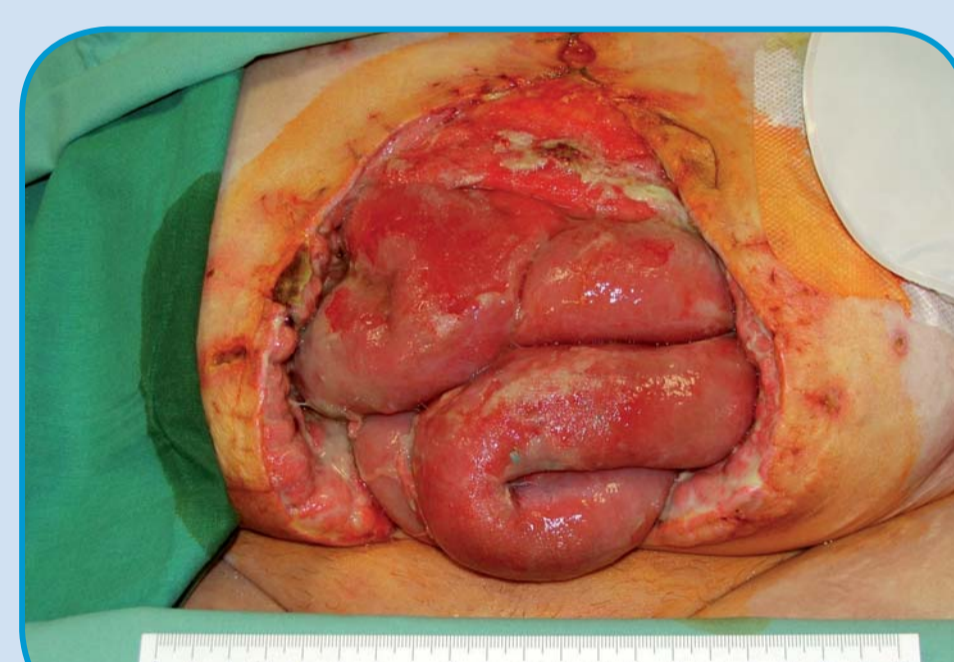


After 5 months patients was sent home. Only large bowel fistula was apparent.

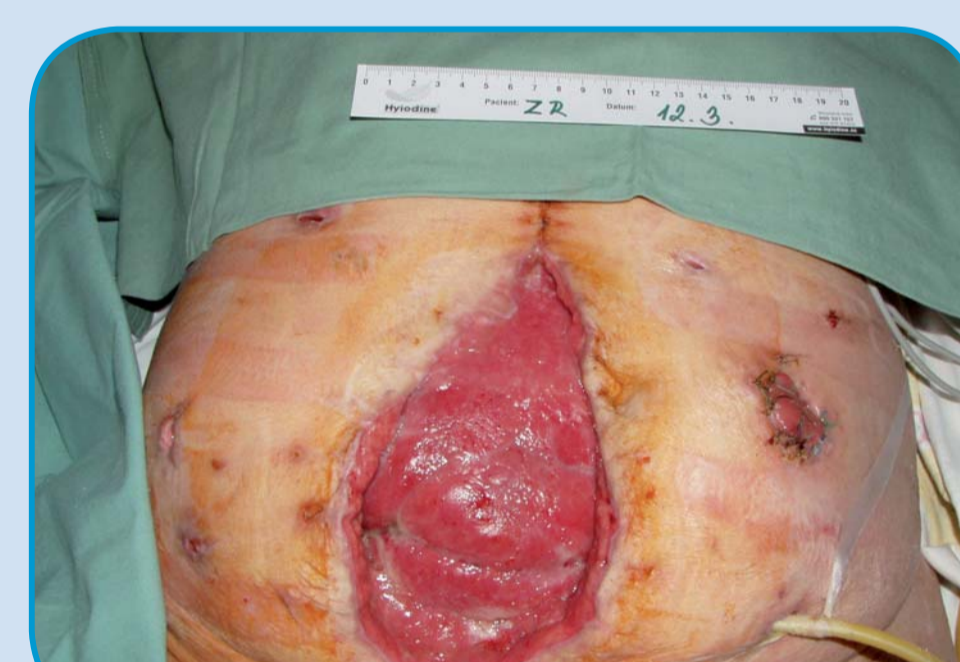

Situation after final operation.

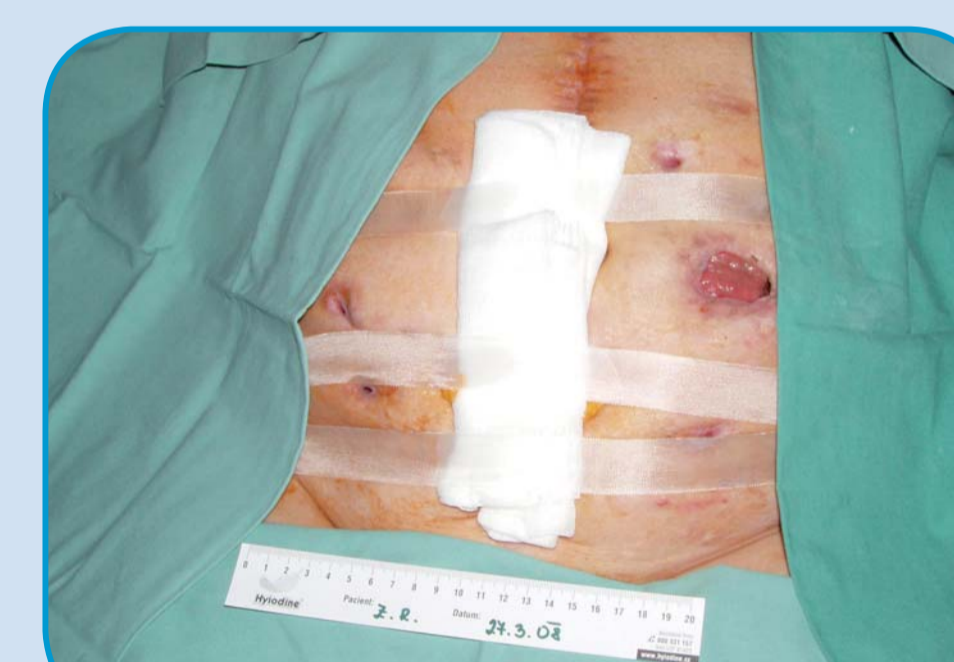CASE 2



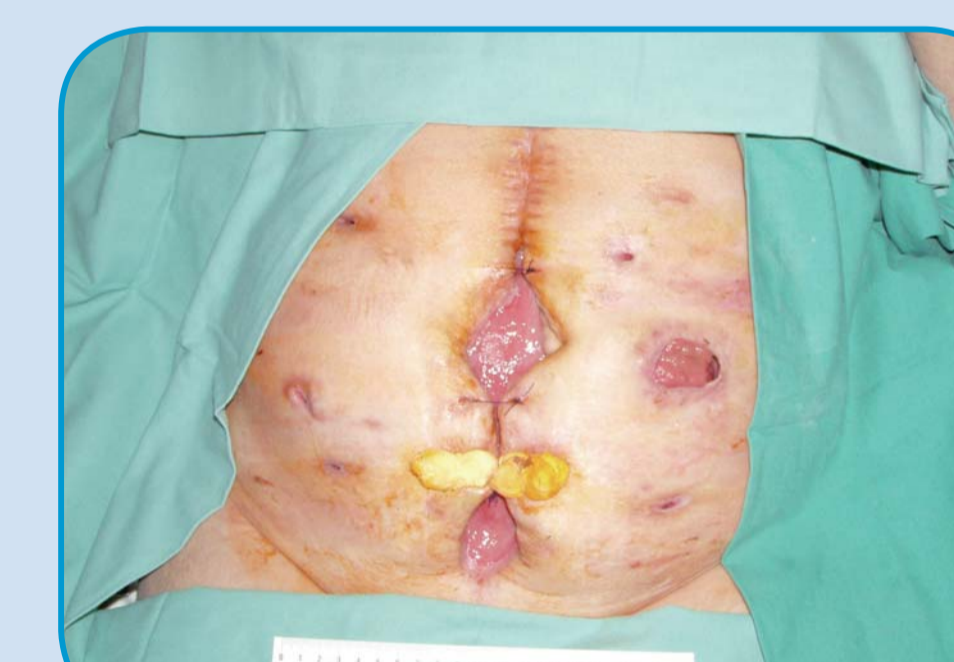
Large wound dehiscence after rectum resection - MRSA positive.



12 days after hyaluronan-iodine complex treatment.

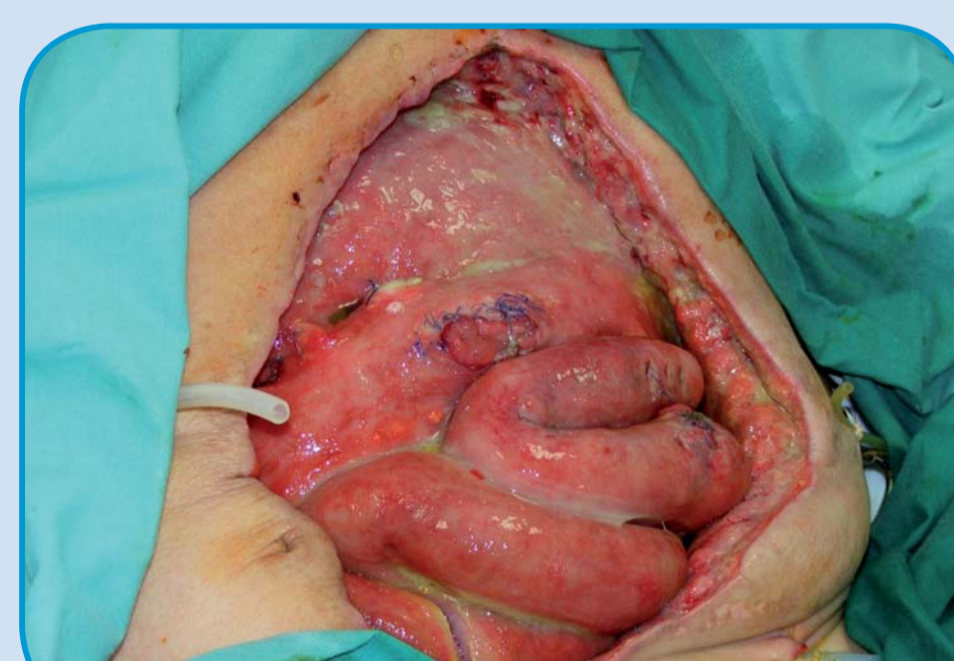

Day 27 skin adaptation using adhesive tape.

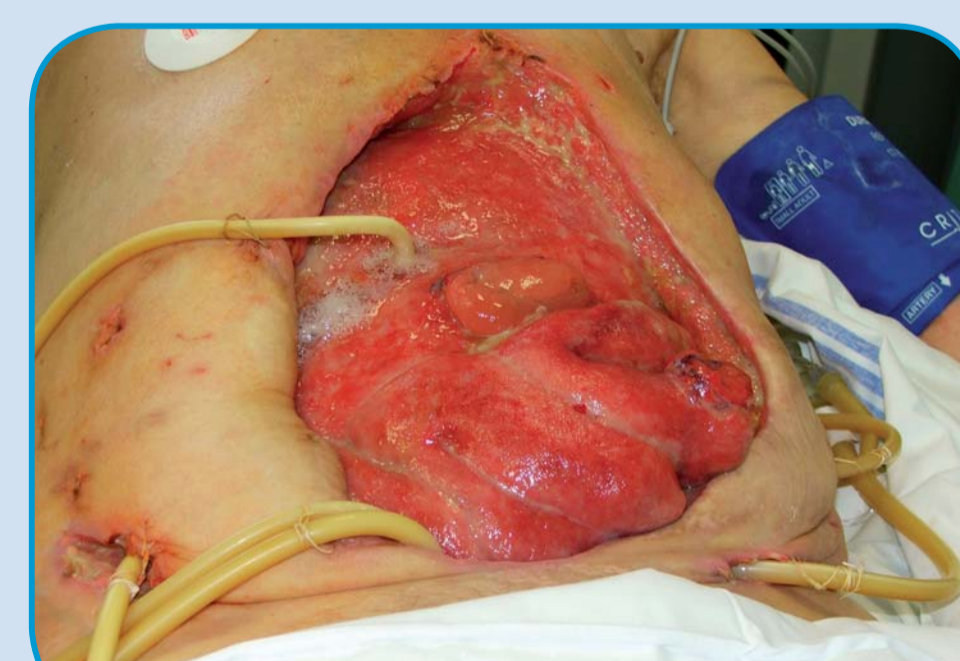

Wound after 27 days of hyaluronan-iodine complex treatment - patient sent home.

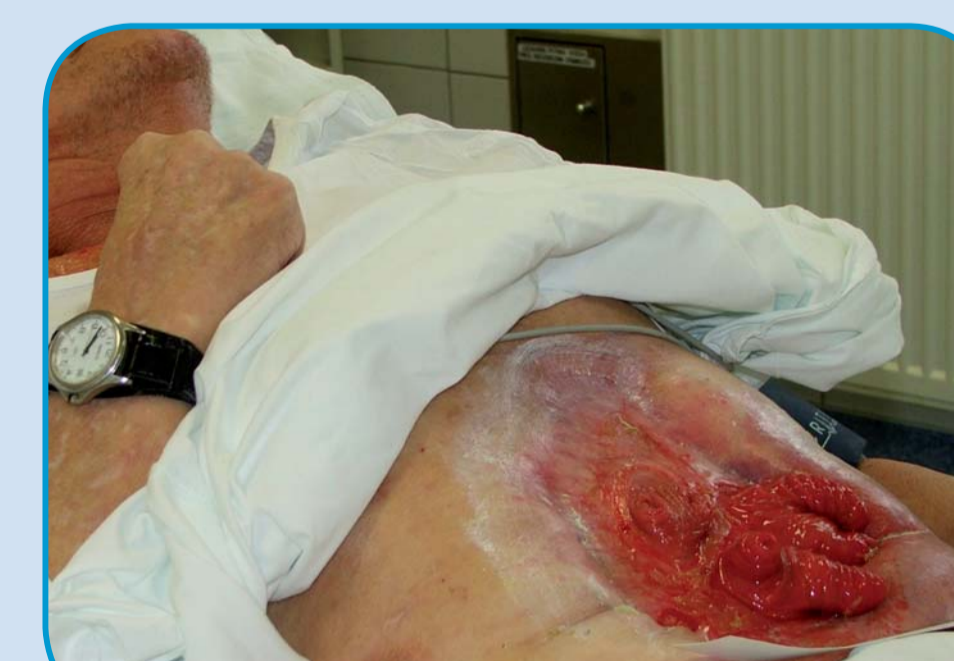CASE 3



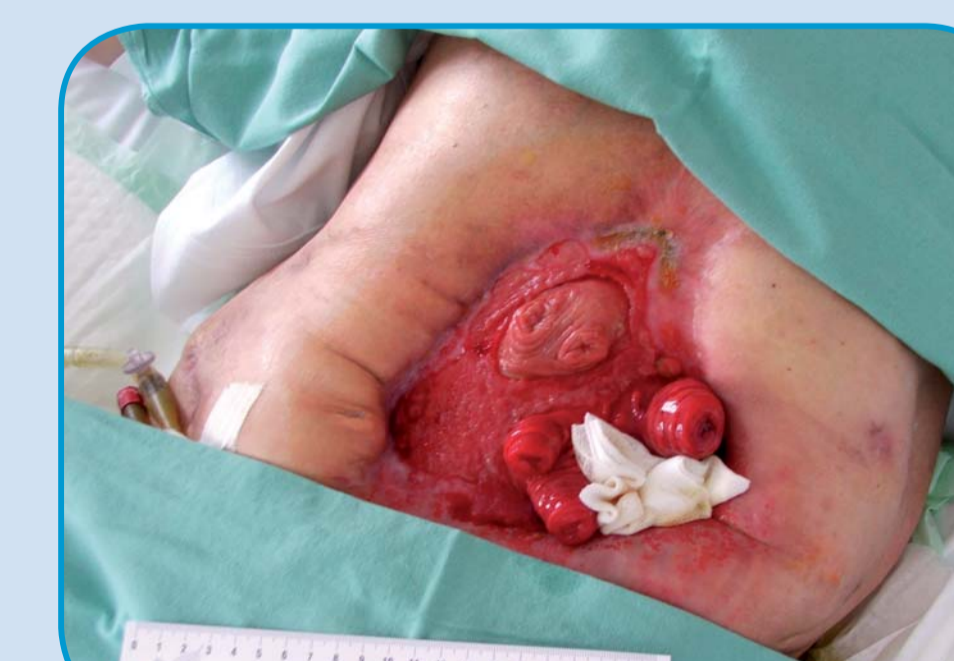Abdominal catastrophe after complicated gastric resection.



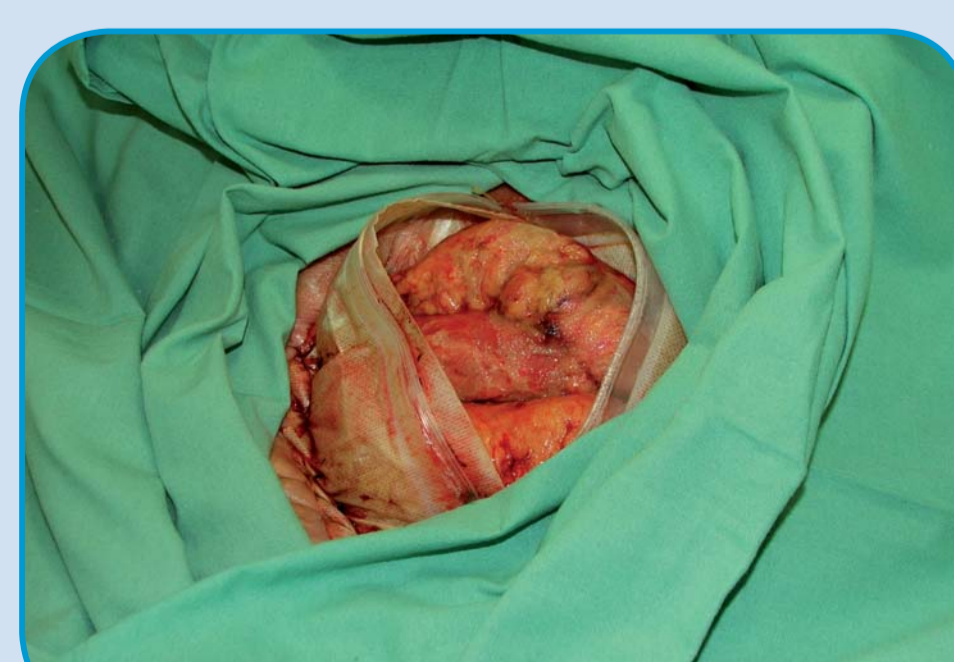Granulated wound after three weeks of hyaluronan-iodine complex treatment.



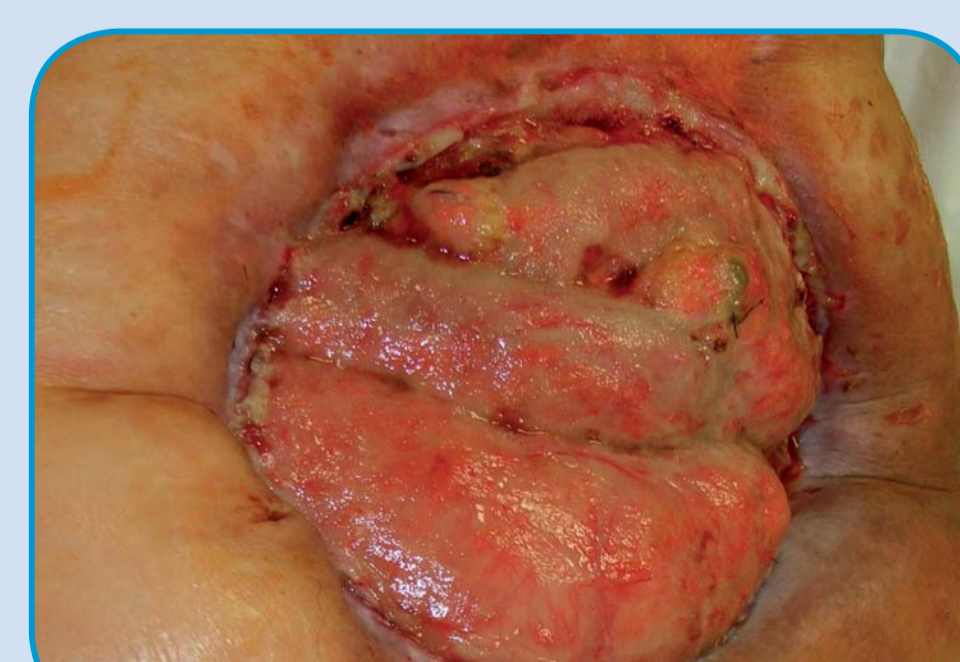Three months after hyaluronan-iodine complex treatment.



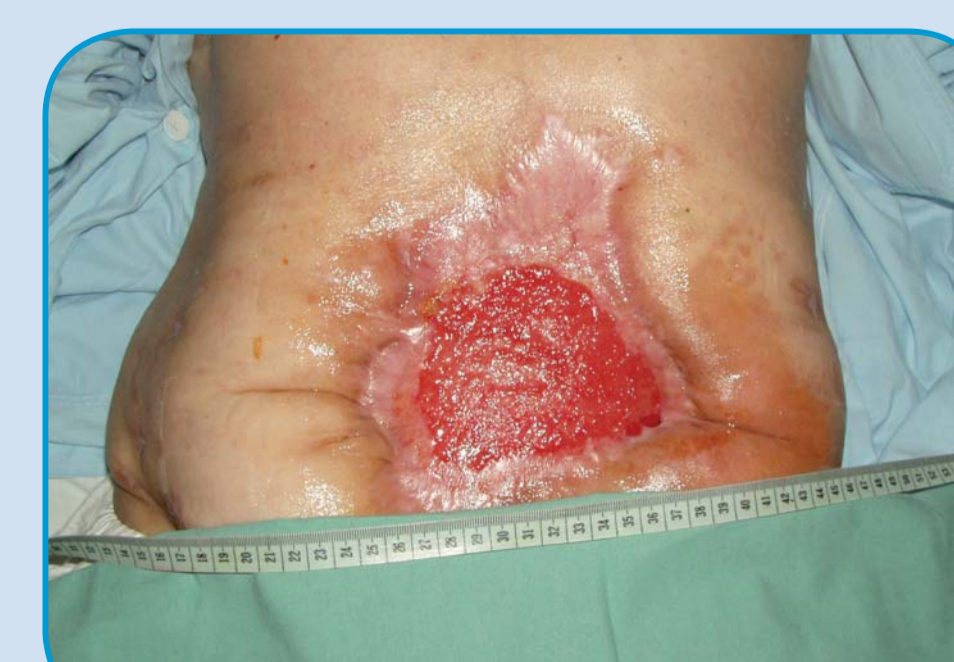Situation before operation.



Dehiscence after operation - hemicolectomy and jejunal resection.



Five days after the second operation and hyaluronan-iodine complex treatment.



One month after operation - patient sent home.